

Dobutamine Stress Echocardiography can Risk Stratify and Prognosticate patients Undergoing Renal Transplantation

SHAFIQ UR REHMAN CHEEMA, SIDRA CHEEMA*

ABSTRACT

Cardiovascular death rate in dialysis and renal transplant (RT) patients is twice, while myocardial infarction (MI) is 3-5 times that of general population. Prognostic value of Dobutamine Stress Echocardiography (DSE) in these patients is limited. The ability of pre-transplant DSE to predict cardiac events (cardiac death, MI, unstable angina, PTCA or CABG) was prospectively evaluated in a group of 46 patients. *Group I: 34 patients* with normal DSE. *Group II: 12 patients* with abnormal DSE. Inducible ischemia in 6 patients & baseline wall motion abnormality (LVEF<40%) in 6 patients. On follow up (4.3 years, r=2-5.5), there was one MI in *group I* and no cardiac death (total cardiac events 1/34, 3%). In *group II*: there was one cardiac death and three patients had an acute MI (total cardiac events: 4/12, 33%, P value=0.013). We concluded that a normal Dobutamine Stress Echocardiography is associated with a benign prognosis in Renal Transplant patients and Dobutamine Stress Echo can risk stratify and prognosticate patients undergoing Renal Transplantation.

Keywords: Renal transplantation, Dobutamine stress echocardiography, chronic kidney disease

INTRODUCTION

Cardiovascular disease is a leading cause of death after renal transplantation. Almost half of the deaths with functioning graft occurring within 30 days after transplantation are as a consequence of cardiovascular disease, primarily acute myocardial infarction (MI). Because many dialysis patients are unable to exercise adequately, noninvasive testing usually takes the form of chemical stress echocardiography or scintigraphy. Patients with positive stress test should proceed to coronary angiogram. Although Dobutamine stress echocardiography (DSE) is cited in clinical guidelines for the evaluation of patients with chronic kidney disease (CKD), there are limited data regarding its prognostic utility in this setting¹. Prognostic value of Dobutamine Stress Echocardiography (DSE) in these patients is limited. The objective of this study was to determine the prognostic value of DSE prior to RT.

MATERIALS & METHODS

We used Dobutamine Stress Echocardiography to examine the "inotropic reserve" of dysfunctional but viable myocardium at rest by the administration of an inotropic agent, with dobutamine being the most frequently used agent. Viable myocardium shows improved global or regional contractile function (inotropic reserve), as assessed by simultaneous transthoracic echocardiography, in response to inotrope administration. A contractile response to

Department of Medicine, Division of Nephrology, CMH Lahore Medical College, Lahore, *Assistant professor of Pathology, Correspondence to Dr. Shafiq ur Rehman Cheema, Assistant Professor, Email: shafiqcheema@yahoo.com Cell: 0311-238-1111

dobutamine appears to require that at least 50 percent of the myocytes in a given segment are viable; the contractile response also correlates inversely with the extent of interstitial fibrosis on myocardial biopsy (3-9)

Study design: Prospective cohort

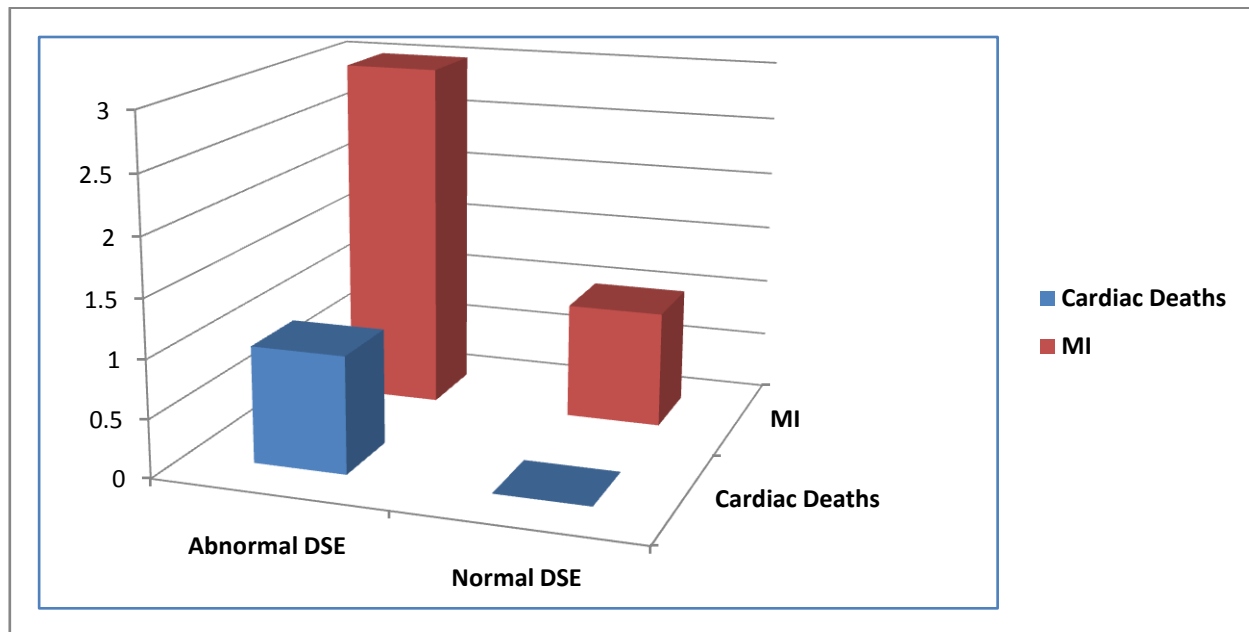
The ability of pre-transplant DSE to predict cardiac events (cardiac death, MI, unstable angina, PTCA or CABG) was prospectively evaluated in a cohort of 46 patients. *Group I: 34 patients* with normal DSE. *Group II: 12 patients* with normal DSE. Inducible ischemia in 6 patients & baseline wall motion abnormality (LVEF<40%) in 6 patients. The group characteristic are shown below.

Characteristics	DSE+(n=12)	DSE-(n=34)	p value
Mean age	59(r=33-73)	58(r=42-69)	NS
HTN	10(83%)	30(88%)	NS
DM	05(42%)	16(47%)	NS
LVH	05(42%)	13(38%)	NS
Mean LVEF	47%(r=35-65)	57%(r=50-65)	0.000137
Follow up (month)	49(r=22-59)	56(r=23-67)	NS

LVH=left ventricular hypertrophy, r=range, LVEF=left ventricular ejection fraction, NS=non-significant, DM= Diabetes,

RESULTS

On follow up (4.3 years, range =2-5.5), there was one MI in *group I* and no cardiac death (total cardiac events 1/34, 3%). In *group II*: there was one cardiac death and three patients had an acute MI (total cardiac events: 4/12, 33%, P=0.013, Mid-P exact.). See below. Cardiac Event, P value=0.013. The relative risk was 11.3 indicating that patients with abnormal DSE were 11.3 times more likely to have a cardiac event as compared to the patients who had normal pre-transplant DSE.



DISCUSSION

The results of our prospective cohort study are statistically significant and indicate the potential value of DSE in risk stratification prior to kidney transplant. Based on the findings one could say that a normal Dobutamine Stress Echocardiography is associated with a benign prognosis in Renal Transplant patients and Dobutamine Stress Echo can risk stratify and prognosticate patients undergoing Renal Transplantation. We recommend that all the patients in which a critical lesion is found on angiogram after an abnormal DSE, should probably undergo correction with coronary artery bypass surgery, angioplasty or stent placement prior to transplantation.

A meta-analysis of myocardial perfusion studies in patients with ESRD referred for kidney and kidney pancreas transplantation concluded that patients with evidence of inducible perfusion abnormality or wall motion abnormality had six fold higher risk of MI and four fold higher risk of cardiac death². This is consistent with findings of our study. These data would suggest that a negative nuclear stress test or DSE in this population is associated with a low event rate for MI and cardiac death following RT

Both DSE and dipyridamolesestamibi have similar sensitivities in detecting coronary artery disease in the non-ESRD population. Specific sensitivities and specificities for ESRD population are lacking¹. The optimal noninvasive test is unclear¹⁰. The optimal choice is generally based upon the expertise of the particular medical center and clinical patient characteristics¹⁰. No data is available on role and

value of DSE prior to RT. A Cochrane review suggested that Dobutamine stress echocardiography and thallium myocardial perfusion scan both have moderate sensitivity and specificity among kidney transplant candidates (10-13). These findings are consistent with our findings and DSE could be used as noninvasive test of choice in low to moderate risk patients. High risk patients are better off undergoing coronary angiogram without the need of prior noninvasive stress test.

In another study by Bergeron et al to assess the prognostic value of DSE in patients with CKD. One hundred eighty-eight (39%) patients died during follow-up. Patients with extensive ischemia (affecting > 25% of myocardial segments) had a 1- and 3-year survival rate of 77% and 48%, respectively, compared with 83% and 52% in those with lesser degrees (< or =25% segments affected) of ischemia and with 88% and 70% in those with a normal DSE. They concluded that in patients with CKD, the percentage of ischemic segments during DSE is an independent predictor of mortality and provides prognostic information that is incremental to clinical data¹⁴.

Cardiovascular disease (CVD) is the major cause of long-term mortality and death with graft function. All patients with CKD are at high cardiac risk, although for some the risk is particularly high. Diabetic patients, older patients, patients on dialysis for prolonged periods and patients with multiple Framingham risk factors for coronary artery disease should undergo noninvasive cardiac testing. Risk factors associated with posttransplant ischemic heart

disease include age greater than 50 years, diabetes and abnormal electrocardiogram. Most transplant centers use noninvasive testing as their initial mode of screening for coronary artery disease, although some prefer to go directly to coronary angiogram.

Since Cardiac death is common in patients with end-stage renal failure. Screening for coronary artery disease prior to renal transplantation is advisable in high-risk patients. The optimal screening test has not been defined; however, myocardial perfusion studies are more sensitive than exercise electrocardiography and are less invasive than coronary angiography, which remains the gold standard. The management of coronary artery disease prior to transplantation is contentious. Revascularization of coronary artery stenoses is associated with high mortality and morbidity in the renal failure population, and there is little data to indicate that most patients with asymptomatic coronary lesions will benefit from prophylactic coronary intervention¹⁵.

Limitation: One limitation of the study is small number of patients and follow up is not very long.

CONCLUSION

A normal Dobutamine Stress Echocardiography is associated with a benign prognosis in Renal Transplant patients and Dobutamine Stress Echo can risk stratify and prognosticate patients undergoing Renal Transplantation. We recommend that Dobutamine Stress Echocardiography could be considered as noninvasive stress test of choice in dialysis population prior to Renal Transplantation.

REFERENCES

1. Chapter from a book. Hand book of Kidney Transplantation, fourth edition, author: Gabriel M. Danovitch. Page 175, Chapter 6-Evaluation of Renal Transplant Candidates.
2. Rabbat CG, Treleaven DJ, Russell JD, et al. Prognostic value of myocardial perfusion studies in patients with end-stage renal disease assessed for kidney and kidney-pancreas transplantation: A meta-analysis. *J Am Soc Nephrol* 2003;14:431-439.
3. Rocchi G, Poldermans D, Bax JJ, et al. Usefulness of the ejection fraction response to dobutamine infusion in predicting functional recovery after coronary artery bypass grafting in patients with left ventricular dysfunction. *Am J Cardiol* 2000; 85:1440.
4. Main ML, Grayburn PA, Landau C, Afridi I. Relation of contractile reserve during low-dose dobutamine echocardiography and angiographic extent and severity of coronary artery disease in the presence of left ventricular dysfunction. *Am J Cardiol* 1997; 79:1309.
5. Barillà F, De Vincentis G, Mangieri E, et al. Recovery of contractility of viable myocardium during inotropic stimulation is not dependent on an increase of myocardial blood flow in the absence of collateral filling. *J Am Coll Cardiol* 1999; 33:697.
6. Nagueh SF, Mikati I, Weilbaecher D, et al. Relation of the contractile reserve of hibernating myocardium to myocardial structure in humans. *Circulation* 1999; 100:490.
7. Baumgartner H, Porenta G, Lau YK, et al. Assessment of myocardial viability by dobutamine echocardiography, positron emission tomography and thallium-201 SPECT: correlation with histopathology in explanted hearts. *J Am Coll Cardiol* 1998; 32:1701.
8. Cornel JH, Bax JJ, Elhendy A, et al. Biphasic response to dobutamine predicts improvement of global left ventricular function after surgical revascularization in patients with stable coronary artery disease: implications of time course of recovery on diagnostic accuracy. *J Am Coll Cardiol* 1998; 31:1002.
9. Afridi I, Kleiman NS, Raizner AE, Zoghbi WA. Dobutamine echocardiography in myocardial hibernation. Optimal dose and accuracy in predicting recovery of ventricular function after coronary angioplasty. *Circulation* 1995; 91:663.
10. Sawada SG, Lewis SJ, Foltz J, et al. Usefulness of rest and low-dose dobutamine wall motion scores in predicting survival and benefit from revascularization in patients with ischemic cardiomyopathy. *Am J Cardiol* 2002; 89:811.
11. Krajnc M, Pečovnik-Balon B, Hojs R, Ruprecht M. Comparison of coronary artery calcification and some coronary artery calcification risk factors in patients on haemodialysis and in patients with type 2 diabetes. *J Int Med Res* 2011; 39:1006.
12. Scandling JD. Kidney transplant candidate evaluation. *Semin Dial* 2005; 18:487.
13. K/DOQI Workgroup. K/DOQI clinical practice guidelines for cardiovascular disease in dialysis patients. *Am J Kidney Dis* 2005; 45:S1.
14. Bergeron S¹, Hillis GS, Haugen EN, Oh JK, Bailey KR, Pellikka PA. Prognostic value of dobutamine stress echocardiography in patients with chronic kidney disease.
15. Pilmore H. Cardiac assessment for renal transplantation. *Am J Transplant* 2006; 6: 659-665.