

Effect of Melatonin on the Morphology of Adrenal Cortex altered by Streptozotocin

YASMEEN MAHAR¹, AMIR ALI SHORO², MARIYAH HIDAYAT³

ABSTRACT

Background: In experimental animal models, Streptozotocin (STZ) causes hypertrophy and disruption of the layers of adrenal cortex, and administration of melatonin protects the adrenal cortex damaged by stress-induced oxidative damage.

Aim: To observe the effect of melatonin on the body weight, serum glucose and ACTH, and morphology of adrenal cortex in STZ treated adrenal glands of albino rats.

Duration of study: 01 November to 15 December 2013.

Study design: Prospective experimental study.

Place of study: Anatomy department at BMSI, JPMC, Karachi.

Methods: Sixty healthy adult albino rats were included in the study and divided equally into 3 groups for 6 weeks. Group-A was taken as control. Group-B received STZ I/P in a dose of 37 mg/kg body weight. Group-C received STZ in the same dose and additionally received 10 mg/100 ml melatonin in drinking water for 6 weeks.

Results: STZ significantly increased serum glucose and decreased weight in group B animals and in group C. Melatonin could not restore serum glucose or the body weights reduced by STZ. However, melatonin preserved the morphology of the layers of adrenal cortex and also restored serum ACTH levels.

Conclusion: Melatonin in diabetic state protects the adrenal cortex from stress induced damage but it cannot reduce hyperglycemia or restore the body weight.

Keywords: Streptozotocin, Melatonin, Diabetes Mellitus, Hyperglycaemia, Adrenal cortex, Albino rats.

INTRODUCTION

Diabetes is one of the fastest growing disease in the world today¹. It is one of the most common endocrine disorders characterized by hyperglycemia due to defects in insulin secretion, insulin function, or both, causing dysfunction in the body general metabolism. Diabetes-induced chronic hyperglycemia leads to alterations in those endocrine glands involved in regulating the body metabolism².

The adrenal gland is an essential stress responsive organ that is part of both HPA axis and sympathoadrenomedullary system³. It is chiefly responsible for releasing hormones in response to stress⁴. STZ is a pancreatic β -cell toxin which induces rapid and irreversible necrosis of these cells⁵. The mechanism of STZ induced β -cell injury involves excessive reactive oxygen species production, lipid peroxidation, protein oxidation and DNA damage leading to β -cell death⁶. Formation of

ROS is thought to be a mediator of cytotoxic actions of STZ, leading to oxidative stress⁶. Oxidative stress may be one of the stresses influencing the regulation of HPA axis⁷.

Melatonin is a well-known free radical scavenger, antioxidant and antiapoptotic agent⁸. It functions at all levels to aid in the ability of organisms to resist the onslaught of damage normally inflicted by radicals and radical-related products⁹. The present study was planned to observe the effect of melatonin on the morphology of adrenal cortex altered by STZ induced hyperglycemia and oxidative stress. The levels of serum ACTH were also measured in all the animals to assess the degree of stress induced by STZ and any change in this parameter brought about by melatonin.

MATERIAL AND METHODS

This study was conducted in the Department of Anatomy, BMSI, JPMC, Karachi, for a period of 6 weeks. In this study, 60 healthy albino rats, both male and female, 90-120 days old, weighing around 250-290 grams, were obtained from the Animal House of BMSI and divided into 3 groups, each containing 20 animals. They were kept in propylene cages, equipped with drinking water bottle and wood chip

¹Assistant Professor, Anatomy Department, Bahria University of Medical and Dental College, Karachi.

²HOD Anatomy Dept, Principal and Dean, Liaquat National Medical College, Karachi

³Assistant Professor, Anatomy Department, Rahbar Medical and Dental College, Lahore.

Correspondence to Dr. YasmeenMahar, House No.140, Street 39, khayaban-e-bukhari, Phase 6, D.H.A., Karachi. Cell: 0300 8296897 Email: Yasmeenmemon1@hotmail.com

floor bedding under natural environment. Food and water were supplied ad libitum.

Group-A was taken as control. Groups-B and C animals were fasted overnight and administered STZ I/P in a dose of 37mg/kg dissolved in freshly prepared 1ml of Citrate buffer at 4 pH only on the first day of the experiment. Group-C received STZ in the same dose as group B and also received melatonin in a dose of 10 mg/100ml orally in drinking water. The serum glucose of the rats was measured at the start of the experiment and then twice weekly by glucose oxidase method from the tail vein by using a glucometer.

The animals were weighed and sacrificed at the end of 6 weeks by using ether anaesthesia. Their abdomen was opened by midline incision and blood was withdrawn by intra-cardiac puncture into polypropylene tubes for ACTH levels determination by elisa kit. The adrenal glands were exposed and carefully dissected and were then fixed in buffered neutral formalin for 24 hours. They were later kept in 70% alcohol overnight. Dehydration was done with ascending strengths of alcohol. They were then cleared in xylene and infiltrated with paraffin at 59 degrees. Paraffin blocks of tissue were made and 5 micron thick longitudinal sections were cut by a rotatory microtome. Sections were mounted on labeled glass slides and stained with H&E¹⁰ for a detailed morphological examination of the adrenal cortex.

RESULTS

There was a normal physiological increase in the weights of the animals belonging to group A, whereas a highly significant decrease in the weights was recorded in animals belonging to group B and C (Table-1). Table-2 shows a highly significant increase ($p < 0.001$) in serum glucose in group B and C rats as compared to group A, Administration of melatonin to group C animals significantly preserved the morphology of the layers of adrenal cortex (Fig-3) as no vacuoles were seen and the size of the cells was also restored.

Table1: Mean± Standard error of mean bodyweight in different groups

Groups	Initial weight of body(grams)	Final weight of body(grams)
A	277 ±1.24	281 ±1.24
B	272 ±1.17	255 ±1.19**
C	281 ±1.56	262 ±1.24**

**Statistically significant at $p < 0.001$ as compared to control group.

The table above shows the highly significant ($p < 0.001$) effect of STZ in reducing body weight.

However, melatonin could not restore the body weight in STZ treated group.

Table2: Mean±Standard error of mean bodyweight in different groups

Laboratory data	Group A(control)	Group B (STZ treated)	Group C (STZ+ Thyroxine)
Initial S. Glucose(mg/dl)	85 ± 0.81	89 ±0.90	85 ±0.920
Final S. Glucose(mg/dl)	89 ±1.75	356±0.880**	339±0.96**

**Statistically significant at $p < 0.001$ as compared to control group.

The table above shows the highly significant ($p < 0.001$) effect of STZ in raising serum glucose levels and no change observed in group C.

Table-3: Change in mean serum ACTH concentration in all 3 groups of Rats

Groups	Treatment Received	Serum ACTH(Pg/ml)
A	Citrate buffer	130 ± 2.10
B	STZ	310 ± 1.28**
C	STZ + Melatonin	138 ± 1.9

**Statistically significant at $p < 0.001$ as compared to control group.

Serum ACTH was significantly increased in group B and significantly restored in group C.

Fig. 1: Photomicrography of 5 microns thick H and E stained section from cortex of adrenal gland in group A control showing capsule (C), zonaglomerulosa (ZG), zonafasiculata (ZF) and zonareticularis (ZR)

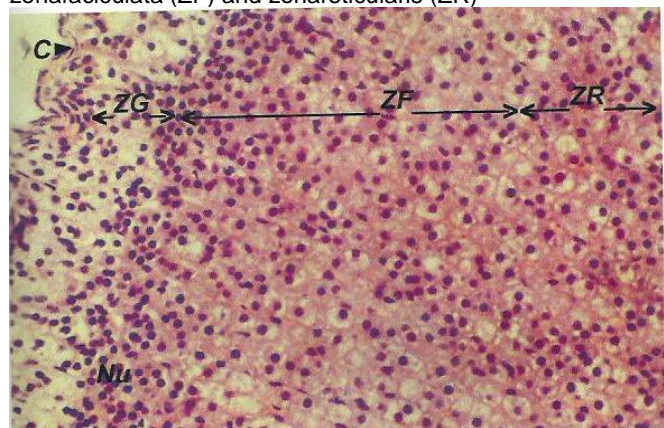


Fig. 2: Photomicrography of 5 micron thick H and E stained section fromCortex of adrenal gland in group B (STZ) treated rat showing zonafasiculata roughly twice the size of control group with fat vacuoles (FV) and increased lipid droplet nuclei (NU) closely packed and pyknotic.

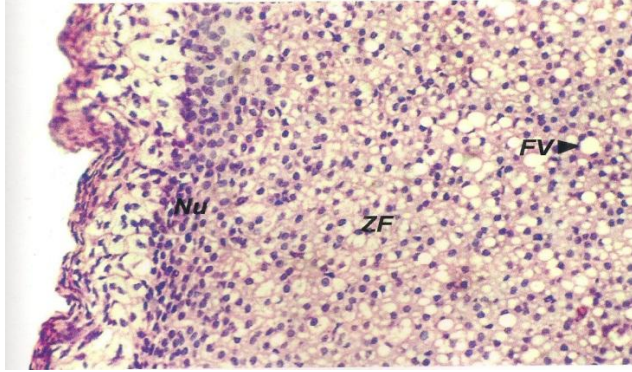
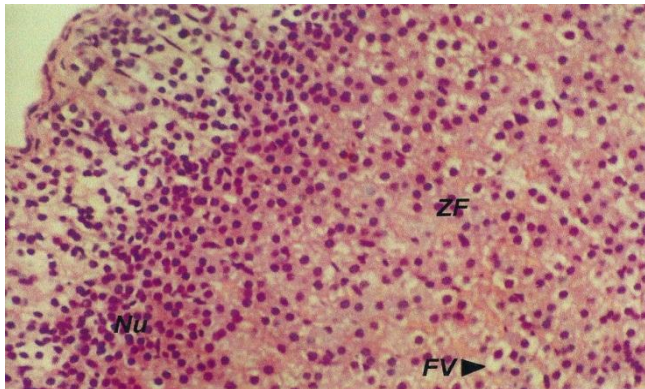


Fig.3: Photomicrograph of 5 micron thick, H and E stained section from the cortex of adrenal gland in group C STZ plus melatonin treated rat showing scanty fat vacuoles and less closely packed nuclei in zonafasciculata, indicating restored cortex.



DISCUSSION

Stress is one of the basic factors in the etiology of a number of diseases. It can stimulate numerous pathways leading to an increased production of the oxidants adding to the oxidant burden associated with normal aerobic metabolism and its consequent damage to lipid, protein and DNA¹¹. For helping an organism to preserve its stability during stress are hypothalamic-pituitary-adrenocortical (HPA) and sympathoadrenomedullary system, both having adrenal glands as terminal effectors¹².

In our study, melatonin could not restore the body weight of the STZ administered rats. Similar findings have been observed by some of the previous studies performed^{13,14}. It is believed that the sympathetic nervous system is responsible for this mechanism by enhancing its effects on both the brown and white adipose tissues, leading to their mobilization and dissipation of energy¹⁴. It was also observed that melatonin could not restore the levels of serum glucose in group C, but it was able to restore the morphology and reduce hypertrophy of the cells of adrenal cortex. Enlargement of the adrenal cortex has been reported after several types

of chronic stress. Both adrenal hypertrophy and hyperplasia have been reported during STZ induced diabetes¹⁵. Repeated exposure to elevated plasma ACTH during chemical stress may stimulate zona fasciculata growth and cause zona glomerulosa atrophy¹⁵. Melatonin significantly reduced the levels of serum ACTH in group C which were markedly elevated by STZ in group B. This could be because melatonin reduces nitric oxide generation within mitochondria, leading to decreased corticosteroid biosynthesis in rat adrenal cells¹⁶.

CONCLUSION

Based on the present study, we come to the conclusion that melatonin significantly restores the morphology of adrenal cortex distorted by STZ induced stress and oxidative damage in albino rats. But it has no effect on serum glucose or body weight altered by STZ. Therefore, it can play a promising role in reducing stress-induced damage of adrenal gland in diabetic patients.

REFERENCES

1. Barron J. Endocrine System & Blood Sugar Levels, Health Newsletter, Part 5, 2015.
2. Elahi-Moghaddam Z, Behnam-Rassouli M, Mahdavi-Shahri N, Hajinejad-Boshroue R, Khajouee E. Comparative study on the effects of type 1 and type 2 diabetes on structural changes and hormonal output of the adrenal cortex in male Wistar rats. 2013;12:9
3. Yvonne M, Ulrich L, Helmer F, Michelle M, Dennis C, William C. Chronic stress induces adrenal hyperplasia and hypertrophy in a sub-region specific manner. *AJP Endo* 2006; 291(5) E965-E973.
4. Pertsov SS. Effect of melatonin on the thymus, adrenal glands, and spleen in rats during acute stress. *Experimental biology and medicine* 2006; 141(3):292-5.
5. Pour PM. *Toxicology of the Pancreas*. 2006, Taylor and Francis Publications, USA.
6. Hidayat M, Mahar Y, Wasim B. Effect of melatonin on serum glucose and body weights in streptozotocin induced diabetes in albino rats. *J Ayub Med Coll Abbottabad* 2015; 27(2).
7. Asaba K. Attenuation by reactive oxygen species of glucocorticoid: Suppression on proopiomelanocortin gene expression in pituitary corticotroph cells. *Endocrinology* 2003, Brief communication.
8. Kim JB, Jung JY, Ahn JC, Rhee CK, Hwang HJ. Antioxidant and Anti-Apoptotic Effect of Melatonin on the Vestibular Hair Cells of Rat Utricles *Clin Exp Otorhinolaryngol*. 2009 Mar; 2(1): 6–12. Published online 2009 Mar 26. doi:10.3342/ceo.2009.2.1.6
9. Reiter, R. J., Manchester, L. C., & Tan, D.-X. (2010). Neurotoxins: Free Radical Mechanisms and Melatonin Protection. *Current Neuropharmacology*, 8(3), 194–210.

10. Bancroft JD and Cook HC.2013. Manual histological techniques and their diagnostic application. Edinburgh: Churchill Livingstone.
11. Yossef EM, Abdel-Hameed MN, Mohamed WW.The effect of melatonin and/or complex vitamin B1,B6, B12 in modulating epinephrine-induced stress in male rats. Braz. arch. biol. technol. 2013, vol.56, n.3 :pp. 393-403
12. Petrovic-Kosanovic D, KsenijaVelickovic K, Koko V, Jasnica N, Cvijic G, Milošević MC. Effect of acute heat stress on rat adrenal cortex - a morphological and ultrastructural study. Cent. Eur. J. Biol. • 7(4) • 2012 • 611-619
13. Anisimov VN, Zavarzina NY, Zabezhinski MA, PopovichIG, Zimina OA, Shtylick AV. Melatonin increases bothlife span and tumor incidence in female CBA mice. J. Gerontol A BiolSci Med Sci 2001;56:B311–23.
14. Bartness TJ, Demas GE, Song CK. Seasonal changes in adiposity: the roles of the photoperiod, melatonin and other hormones, and sympathetic nervous system. ExpBiol Med 2002;227:363–76.
15. Mahar Y, Shoro A A,Naqvi A. The effect of L-arginine and insulin on histological changes in STZ treated rat adrenal gland.PJMHS2012;vol.6,issn.19:pp843-846.
16. Mansouri A, Demeilliers C,Amsellem S, PessayreD, Fromenty B. Acute Ethanol Administration Oxidatively Damages and Depletes Mitochondrial DNA in Mouse Liver, Brain, Heart, and Skeletal Muscles: Protective Effects of Antioxidants.JPET.2001; vol. 298, no. 2:737-743.