

# Desarda Technique for Inguinal Hernia Repair, a multicenter experience

SHEHZAD BASHIR<sup>1</sup>, MUHAMMAD OMAR AFZAL<sup>2</sup>, YASEEN RAFI<sup>3</sup>

## ABSTRACT

**Background:** Recently introduced tension free Desarda technique for inguinal hernia repair is relatively less employed in the centers worldwide. The data available to assess the outcome of this technique is less due to centers conventionally using old and reliable techniques, such as Lichtenstein's repair.

**Methods:** This prospective study was conducted at Jinnah Hospital Lahore and Allama Iqbal Memorial Hospital, Sialkot, from July 2013 to June 2014. We included male patients with unilateral inguinal hernia. Patients with bilateral inguinal hernia, recurrent hernia, obstructed or strangulated hernia and those with mental or other co-morbid conditions were excluded. Patients with weak or divided external oblique aponeurosis were also excluded. Desarda repair was done on 50 cases and patients were followed for 3 months and complications were noted to assess the outcome.

**Results:** Total number of cases was 50. Mean age was 49.9±13.4 years. Patients with right sided inguinal hernia were 62%, while 38% with left. 14% patients developed post op haematoma, 5% developed seroma, 14% developed surgical site infection, 8% chronic pain and none developed recurrence. Overall complication was noted in 10(20%) out of 50 patients.

**Conclusion:** Desarda repair is safe and effective for inguinal hernia with very low rate of recurrence. It avoids foreign material in the form of mesh, and low cost in terms of exclusion of mesh.

**Keywords:** Inguinal Hernia, Desarda Technique.

---

## INTRODUCTION

Inguinal hernia is a frequent case to come across in the outpatient clinic as well as in emergency. Because of its frequency, it remains a common, yet an important medical problem. For men, there is a 27% lifetime risk to develop inguinal hernia, while in women it remains at 3%<sup>1</sup>. Although European Hernia Society promotes Lichtenstein repair to deal with this frequent clinical case, Shouldice repair is also being popularised<sup>2</sup>. Totally extraperitoneal (TEP) inguinal hernia repair has also gained acceptance in recent times with good outcomes<sup>3</sup>. This technique, however, has a longer learning curve, and requires a precise anatomical knowledge of the surgical field which is a major constraint in its adoption in tertiary care centers of Pakistan<sup>4,5</sup>. Desarda technique is a recently introduced tissue based repair that addresses physiology of the inguinal canal as well as the anatomy. Tissue-based repairs like Bassini and Desarda confer an advantage of using less prosthetic material. Desarda technique, like Lichtenstein, is a tension free repair with less recurrence rates

comparable to Lichtenstein, and requires less per-operative time<sup>6</sup>. Despite its advantages, it is relatively less employed in the centers worldwide. The data available to assess the outcome of this technique is less due to centers conventionally using old and reliable techniques, such as Lichtenstein's repair. Thus we have used this technique to repair inguinal hernia in elective cases to check the validity of its advantages and compare the results with other commonly used techniques to repair inguinal hernia.

## METHODS

This prospective study was conducted at surgical unit-1, Jinnah Hospital Lahore and Allama Iqbal Memorial Hospital, Sialkot. The study period was one year, from July 2013 to June 2014. We included male patients with unilateral inguinal hernia. While patients with bilateral inguinal hernia, recurrent, obstructed or strangulated hernia and those with mental or other co-morbid conditions were excluded. Patients with weak or divided external oblique aponeurosis were also excluded. Desarda repair was done on 50 cases who were admitted in the inpatient department for elective surgery of inguinal hernia. Detailed history, examination and investigations were done on all patients to assess fitness and to rule out co-morbid conditions. Patients were also evaluated for any

---

<sup>1</sup>Assistant Professor Surgery, Kh. Muhammad Safdar Medical College Sialkot

<sup>2</sup>P G R, Surgical Unit-1, Jinnah Hospital Lahore.

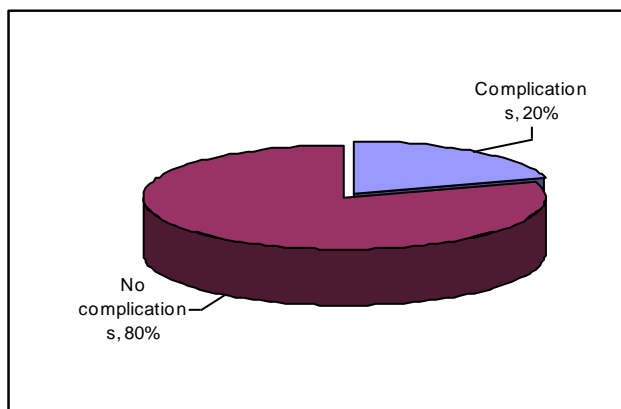
<sup>3</sup>Associate Professor, AIMC, Kh. Muhammad Safdar Medical College Sialkot

Correspondence to Dr. Yaseen Rafi, Associate Professor Email: dryaseenrafi@yahoo.com cell: 03334245123

predisposing condition for inguinal hernia. Patients with obvious predisposing condition were managed accordingly before surgery was done. Desarda repair was done after taking informed consent from each patient. Patients were followed for 6 months post operatively, and complications were noted and rates calculated to assess the outcome.

## RESULTS

Total number of patients included in the study was 50. The mean age of patients that were operated was  $49.9 \pm 13.4$  years. There were 31 patients with right sided inguinal hernia. While there were 19 patients with left sided inguinal hernia that were included in this study. Post op haematoma was noted in 7(14%) patients. Rest of the 43(86%) patients did not develop haematoma post operatively at the surgical site. Haematoma once developed, was drained to prevent further complications. 5(10%) out of 50 patients, developed seroma at the surgical site which was evacuated and compression garments prescribed to prevent further collection. 7(14%) out of 50 patients developed surgical site infection. It was managed accordingly after assessing the severity. 4(8%) patients developed chronic pain after the surgical procedure. There was no recurrence of inguinal hernia noted among the patients who underwent Desarda repair. The pie chart shows the percentage of patients who developed complications post operatively after undergoing Desarda repair in our study.



## DISCUSSION

The Desarda technique to repair inguinal hernia is a novel technique and utilises body tissues to strengthen the weakness in the abdominal wall, although initially the objections were presented by some authors about it being a modification of old methods<sup>6,7</sup>. With the advent of new techniques, discussion however continues as to which is the gold

standard for repair of inguinal hernia repair. Apart from laparoscopic repair, Lichtenstein repair remains the gold standard against which the tissue based Desarda repair is most commonly compared. There are however some topics of debate regarding Lichtenstein technique itself. Of these, surgical site infection is seen among the patients who are treated with prosthetic mesh, along with migration of mesh which poses even a serious problem<sup>8,9,10</sup>

The recurrence rate, however is less in Lichtenstein repair as compared to other repairs previously described<sup>11</sup>. The mean recurrence rate for the Lichtenstein procedure is approximately 1% in semispecialised hospitals but it can be much higher when data from community hospitals (about 4%) is analysed, and can even reach 18% in some articles<sup>12</sup>. The data available for various other mesh techniques vary from 0 to 4.2% recurrences for Prolene Hernia System (PHS), 1.6 to 19% for the Transabdominal Pre-Peritoneal inguinal hernia repair (TAPP) and 0 to 4% for Rutkow<sup>12,13,14</sup>. Our study demonstrates a low complication rate and no recurrence for Desarda technique, which puts this technique in line with the highly recognized Lichtenstein technique to repair the inguinal hernia.

The cost of the treatment for this disease, when mesh technique is used, becomes real issue in the modern era and though the cost of inguinal hernia treatment is not insignificant when considered as a fraction but in the developing countries of Africa or Asia, it does. Thus the advantage of Desarda repair, in it being of relatively low cost, and speaks for the fact that many recently published articles demonstrated an increasing interest in the Desarda repair<sup>15,16</sup>.

Apart from the economical issues, the use of prosthetic mesh is a topic of discussion and conflict in young patients. There is still no data reflecting the long term effect of synthetic mesh on the human body, and thus this point is entirely unknown. There is also scanty but documented evidence that shows decrease in male sexual function, and this makes a surgeon to prefer tissue based technique when dealing with a young patient. Contaminated field as seen during surgery for strangulated hernias also promotes the use of tissue-based technique, such as Desarda, to be used frequently<sup>17</sup>.

## CONCLUSION

Desarda technique is a safe and effective technique to repair inguinal hernia and has a low rate of recurrence and complication. It avoids incorporation of foreign material in the form of prosthetic mesh, in the human body, as well as, has lower cost in terms of exclusion of mesh from the procedure.

Comparative studies and studies revealing data of Desarda technique in emergency cases, should be done to further evaluate the effectiveness of this technique.

## REFERENCES

1. Primatesta P, Goldacre MJ Inguinal hernia repair: incidence of elective and emergency surgery, readmission and mortality. *Int J Epidemiol* (1996) 25:835–839
2. Simons MP, Aufenacker T, Bay-Nielsen M et al European Hernia Society guidelines on the treatment of inguinal hernia in adult patients. *Hernia* (2009) 13:343–403
3. Dulucq JL, “Treatment of inguinal hernias by inserting a subperitoneal prosthetic patch using preperitoneoscopy (with a video film),” *Chirurgie: Memoires de l’Academie de Chirurgie*, vol. 118, no. 1–2, pp. 83–85, 1992
4. Lau H, Patil NG, Yuen WK, Lee F. “Learning curve for unilateral endoscopic totally extraperitoneal (TEP) inguinal hernioplasty,” *Surgical Endoscopy and Other Interventional Techniques*, vol. 16, no. 12, pp. 1724–1728, 2002.
5. Choi YY, Kim Z, Hur KY, “Learning curve for laparoscopic totally extraperitoneal repair of inguinal hernia,” *Canadian Journal of Surgery*, vol. 55, no. 1, pp. 33–36, 2012.
6. Losanoff JE, Richman BW, Jones JW Inguinal herniorrhaphy with an undetached strip of external oblique aponeurosis: old or new? *Eur J Surg* (2001) 167:877
7. Losanoff JE, Millis JM Aponeurosis instead of prosthetic mesh for inguinal hernia repair: neither physiological nor new. *Hernia* (2006) 10:198–199 author reply 200–102
8. Genc V, Ensari C, Ergul Z et al A very late-onset deep infection after prosthetic inguinal hernia repair. *Chirurgia (Bucur)* (2010) 105:555–557
9. Jeans S, Williams GL, Stephenson BM Migration after open mesh plug inguinal hernioplasty: a review of the literature. *Am Surg* (2007) 73:207–209
10. Benedetti M, Albertario S, Niebel T et al Intestinal perforation as a long-term complication of plug and mesh inguinal hernioplasty: case report. *Hernia* (2005) 9:93–95
11. Heikkinen T, Bringman S, Ohtonen P, et al. Five-year outcome of laparoscopic and Lichtenstein hernioplasties. *Surg Endosc*. 2004;18:518–22.
12. Eklund A, Rudberg C, Smedberg S et al Short-term results of a randomized clinical trial comparing Lichtenstein open repair with totally extraperitoneal laparoscopic inguinal hernia repair. *Br J Surg* (2006) 93:1060–1068
13. Hasegawa S, Yoshikawa T, Yamamoto Y et al Long-term outcome after hernia repair with the prolene hernia system. *Surg Today* (2006) 36:1058–1062
14. Adamonis W, Witkowski P, Smietanski M et al Is there a need for a mesh plug in inguinal hernia repair? Randomized, prospective study of the use of Hertra 1 mesh compared to PerFix Plug. *Hernia* (2006) 10:223–228
15. Situma SM. Comparison of Desarda versus modified Bassini inguinal Hernia repair: a randomized controlled trial. *East Cent Afr J Surg* (2009) 14:70–76
16. Desarda MP A new technique of inguinal hernia repair— neither similar to nor modification of Desarda repair. *J Indian Med Assoc* (2007) 105:654
17. Szopinski J, Dabrowiecki S, Pierscinski S, Jackowski M, Jaworski M, Szuflet Z. Desarda versus Lichtenstein technique for primary inguinal hernia treatment: 3-year results of a randomized clinical trial. *World J Surg* 2012; 36: 984–992.