

Alternative Treatment of Shoulder Adhesive Capsulitis with Single Dose Intraarticular Sodium Hyaluronate

ADEEL HAMID, SYED BAQIR HUSSAIN JAFREE, RASHID SAEED, NUSRAT ALI

ABSTRACT

Objective: To check the efficacy of single dose intra-articular hyaluronate injection for treatment of patients with shoulder adhesive capsulitis

Study design: Randomized clinical trial on 40 cases

Setting: Department of Orthopaedics, Jinnah Hospital, Lahore.

Duration with dates: 06 months (1st April 2012 to 30th September 2012).

Subjects and methods: Forty patients with adhesive capsulitis, fulfilling the selection criteria were identified. After proper assessment including Constant shoulder score, all patients received intra-articular Sodium hyaluronate injection in the outpatient department. Patients were asked to take simple analgesics if required and follow similar home exercise programs for two weeks.

Results: A total of 40 patients were included in the study. 13(32.5%) were males and 27(67.5%) were females. The age ranged from years 39-73 years. Mean age of patients was 55.11 ± 7.16 . Clinical improvement as assessed by Constant Shoulder Score was seen in 37/40 patients. Mean Constant Shoulder Score was 37.27 ± 14.45 and after 2 weeks of treatment with sodium hyaluronate injection the mean score improved to 54.14 ± 13.88 .

Conclusion: Although the study was done on a limited number of patients, it establishes single dose intra-articular Sodium hyaluronate injection as an effective and safe treatment alternative for the pain and disability associated with adhesive capsulitis.

Key words: Adhesive capsulitis, Sodium hyaluronate, Corticosteroids.

INTRODUCTION

Adhesive capsulitis (also termed frozen shoulder, stiff painful shoulder or periarthrititis) is a common cause of persistent shoulder pain and disability^{1,3,10}. In spite of availability of various treatment techniques, treatment of frozen shoulder or adhesive capsulitis is generally unsatisfactory. Recommended approaches have been physical therapy, intra articular steroid injection, closed manipulation, arthroscopic capsular release and recently, intra articular hyaluronic acid injections^{1,2,3,4,8,10}.

Adhesive capsulitis (AC) of the shoulder is characterized by spontaneous onset of gradually progressive shoulder pain and limitation of passive glenohumeral movement in all planes. Typically, the movements are restricted in a characteristic pattern with proportionally greater passive loss of internal rotation than abduction and external rotation. The diagnosis is predominantly made on history and

physical examination, with a normal radiograph of the shoulder excluding other serious joint pathologies. Relieving pain and restoring of normal shoulder function is the common aim of various methods used in the treatment. Treatment is generally unsatisfactory. Recommended approaches have been physical therapy, intraarticular steroid injections, closed manipulations, arthroscopic capsular release, nerve blocks, and intraarticular hyaluronic acid injections. Physical therapy is widely used and generally held to be beneficial. Corticosteroids are by far the most commonly used agents for local injections in adhesive capsulitis. Extensive research has been conducted on sodium hyaluronate, a major component of connective tissue. Sodium hyaluronate relieves pain and has metabolic effects on articular cartilage, synovial tissue, and synovial fluid. Sodium hyaluronate is a safe and effective treatment for patients with osteoarthritis of the knee and adhesive capsulitis of the shoulder. In this study, we tested the efficacy of single dose Sodium hyaluronate injection as an alternate modality for the treatment of disability associated with shoulder adhesive capsulitis.

Department of Orthopaedic Surgery, Allama Iqbal Medical College/Jinnah Hospital, Lahore

*Correspondence to Dr. Adeel Hamid, Senior Registrar
Email: adeel_hamid@hotmail.com and*

*Dr. Syed Baqir Hussain Jafree, Assistant Professor
Email: drbaqar@hotmail.com, Cell: 923334267674*

MATERIALS AND METHODS

All participants were informed about the study. This study was carried out with the prior approval of The Ethics Committee of Jinnah Hospital, Lahore, Pakistan. Forty patients with adhesive capsulitis, fulfilling the selection criteria were identified. 27(67.5%) were females and 13(32.5%) were males. The age ranged from years 39-73 years. Mean age of patients was 55.11 ± 7.16 .

Inclusion criteria were:

- Pain predominantly in one shoulder lasting for more than 3 months and less than 2 years on history
- Limitation of passive movement at the glenohumeral joint compared with the unaffected side, more than 30 degrees for at least 2 planes (forward flexion, abduction, and internal rotation) on constant shoulder score
- Age >18 years and <70 years

Exclusion criteria were:

- Unwillingness to participate in the trial
- Trauma to the shoulder in the last 6 months requiring hospital care as indicated by history
- Reason to suspect rotator cuff tear (weakness of arm elevation, a positive drop arm sign, a high riding humeral head on plain X rays).
- Pain and reduction of glenohumeral range of motion as evaluated by clinical examination for reasons other than 'classic' adhesive capsulitis e.g., X ray signs of glenohumeral osteoarthritis or dislocation.
- Serious mental illness as shown by previous medical records
- Various contraindications to injections: allergy to injection material, blood coagulation disorders, and local soft tissue infection as indicated by history and clinical examination
- Suspicion of Septic arthritis of the shoulder on clinical examination
- Clinical evidence of inflammatory arthropathy
- Intra-articular injection of corticosteroids in any joint within the previous month

The diagnosis of adhesive capsulitis was established on the basis of clinical history of spontaneous shoulder pain, shoulder examination showing passive limitation of movements in at least two planes and plain x-rays excluding other significant shoulder diseases. Demographic variables of the patients were recorded. After proper selection, assessment of pain and functional status of the shoulder was done using Constant Shoulder Score. All 40 patients received one intra-articular injection of Sodium hyaluronate (2mL at 10mg/mL). All intra-articular injections were given in the outpatient department under aseptic measures using anterior or

posterior approach by the same surgeon without the aid of imaging modalities. Sterile technique was used to avoid inducing septic joints. Disposable needles and syringes were used and iodine and alcohol were used to prepare the skin.

After the procedure patients were discharged with advice to follow a set of similar range of motion exercises twice a day for 2 weeks at home. Patients were also advised to take simple analgesics (paracetamol 500 mg) as required.

Patients were re-evaluated after 2 weeks. Subjective pain as reported by the patient, functional assessment, clinical assessment of the range of motion of the glenohumeral joint in four directions as measured with the help of a goniometer and shoulder strength (measured with the help of a spring balance) was used to calculate Constant shoulder score. Improvement in Constant shoulder score of the patients 2 weeks after treatment was used to determine the effectiveness of treatment.

RESULTS

The age ranged from 39 to 70 years. Mean age of patients was 55.11 ± 7.16 years. Thirteen patients were male and 27 were female (Fig. 1), making the male to female ratio of 2:5. In 25 patients the left shoulder was involved whereas 11 patients showed involvement of right shoulder. In 4 patients there was bilateral involvement of shoulders (Fig. 2). 24 patients presented with pain and limitation of movement at the shoulder whereas 9 patients had painless limitation of movement and 7 had pain as their chief complaint. 26 patients had diabetes, 3 patients were known cases of ischemic heart disease, and 1 patient had rheumatoid arthritis as a possible predisposing factor to shoulder adhesive capsulitis. Ten patients did not report any comorbidity (Table 1).

All patients included in the study were able to comply with the instructions regarding home exercise program for 2 weeks after intra articular injection. 25 patients had to use simple oral analgesics as required during the 2 weeks prior to follow up whereas 15 patients did not require any analgesics. 37 out of 40 patients that received intra articular sodium hyaluronate reported improvement of symptoms after 2 weeks of treatment whereas 3 patients did not report any improvement with treatment. The mean Constant Shoulder Score in the patients before treatment was 37.27 ± 14.45 and after 2 weeks of treatment with SH injection the mean score improved to 54.14 ± 13.88 . No complications were encountered in any patient at the time of inj

Figure 1

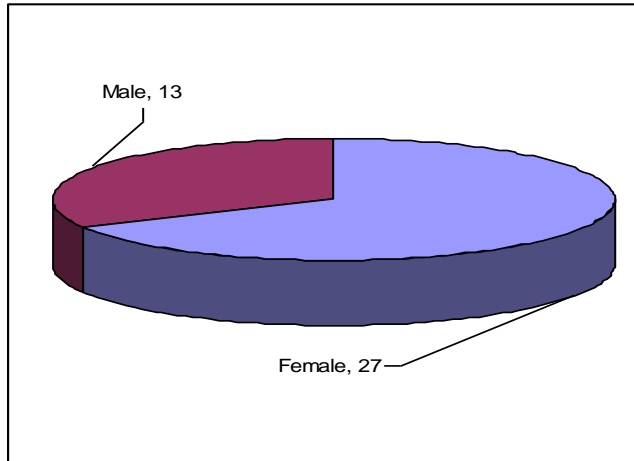


Figure 2

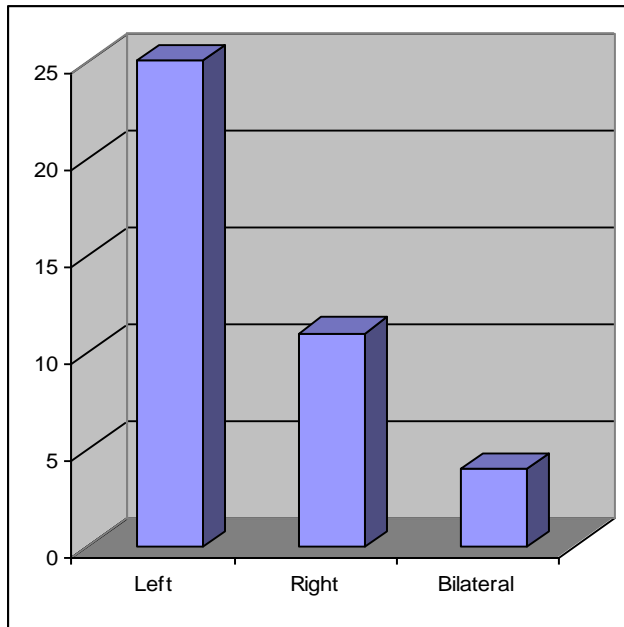


Table 1:

Co-morbidities in patients	=n
Diabetes Mellitus	26
Ischemic heart disease	3
Rheumatoid arthritis	1
None	37

Table 2:

Injection approach used	=n
Anterior approach	13
Posterior	27

Table 3: Mean constant shoulder score

Before treatment	37.27±14.45
2 weeks after treatment with Sodium hyaluronate	54.14±13.88

DISCUSSION

Many modalities for the treatment of shoulder adhesive capsulitis have been devised and tested over the period of time, yet a satisfactory treatment remains elusive. Various treatment used include physical therapy, intra-articular steroid injection, closed manipulation, arthroscopic capsular release and recently, intra-articular hyaluronic acid injections. The emphasis of treatment has been on non-operative methods, with physical therapy and intra-articular corticosteroid injections being the most commonly practiced, especially in our part of the world.

Research has shown that in most cases of adhesive capsulitis there is an element of underlying osteoarthritis of the glenohumeral joint. Therefore after the recent success of Sodium hyaluronate in treatment of knee osteoarthritis it was postulated that Sodium hyaluronate could be effective in the alleviating the pain and limitation of range of movement associated with adhesive capsulitis. Till date only a handful of studies have been done to demonstrate the efficacy of Sodium hyaluronate in adhesive capsulitis. Even those studies are undecided regarding the number of injections required. In most studies 2-5 injections of Sodium Hyaluronate have been tried with variable dosing intervals. In our study single dose regime was utilized keeping in mind the financial restraint, however it proved to be successful in treating the symptoms and disability faced by patients of adhesive capsulitis with 37 out of 40 patients showing an improvement in the Shoulder constant score. These results are similar to those reported by Calis et al¹⁰, Rovetta et al¹², and Itokazu et al¹¹; although these scientists used different dosing intervals with different number of injections. No side effect was reported further strengthening the established safety profile of Sodium hyaluronate. Therefore, we recommend that single dose intra-articular Sodium hyaluronate in conjunction with physical therapy can be used as an effective alternative treatment for shoulder adhesive capsulitis.

REFERENCES

1. Buchbinder R, Hoving J, Green S, Hall S, Forbes A, Nash P. Short course prednisolone for adhesive capsulitis (frozen shoulder or stiff painful shoulder): a randomized, double blind, placebo controlled trial. *Ann Rheum Dis.* 2004;63:1460-1469.
2. Baline T, Mosokowitz R, Udell J, Skyhar M, Levin R, Friedlander J. Treatment of persistent shoulder pain with sodium hyaluronate: a randomized, controlled trial. *J Bone Joint Surg Am.* 2008;90:970-9.
3. Dias R, Cutts S, Massoud S. Frozen shoulder. *BMJ* 2005;331:1453-1456 .

4. Skedros JG, Hunt KJ, Pitts TC. Variations in corticosteroid/anesthetic injections for painful shoulder conditions: comparisons among orthopaedic surgeons, rheumatologists, and physical medicine and primary-care physicians. *BMC Musculoskelet Disord.* 2007; 8: 63. Published online 2007 July 6. doi: 10.1186/1471-2474-8-63.
5. Edwards S, Bell J, Blaine T. Inflammation and shoulder pain-a prespective on rotator cuff disease, adhesive capsulitis, and osteoarthritis. *Business Breifing: Us Orthopedic Review* 2006.
6. Fernandez-Palazzi F, Viso R, Boadas A, Ruiz-Saez A, Caviglia H, De Bosch NB. Intra-articular hyaluronic acid in the treatment of haemophilic chronic arthropathy. *Haemophilia.* 2002;8:375-81.
7. Tamai K, Mashitori H, Ohno W, Hamada K, Sakai H, Saotome K. Synovial response to intra-articular injection of hyaluronate in frozen shoulder: a quantitative assessment with dynamic magnetic resonance imaging. *J Orthop Sci.*2004;9:230-4.
8. Andrews JR. Diagnosis and treatment of chronic painful shoulder: review of nonsurgical interventions. *Arthroscopy.* 2005;21:333-47.
9. Constant C R, Murley A H G. A clinical method of functional assessment of the shoulder. *Clinical Orthopaedics and Related Research* 1987; 214: 160-164.
10. Calis M, Demir H, Ulker S et al. Is intraarticular sodium hyaluronate injection an alternative treatment in patients with adhesive capsulitis?. *Rheumatol Int.* Apr 2006;26(6):536-40.
11. Itokazu M, Matsunaga T. Clinical evaluation of high-molecular-weight sodium hyaluronate for the treatment of patients with periarthritis of the shoulder. *Clin Ther.* Sep-Oct 1995;17(5):946-55.
12. Rovetta G, Monteforte P. Intraarticular injection of sodium hyaluronate plus steroid versus steroid in adhesive capsulitis of the shoulder. *Int J Tissue React.* 1998;20(4):125-30.
13. Wohlgethan JR. Frozen shoulder in hyperthyroidism. *Arthritis Rheum.* Aug 1987;30(8):936-9.
14. Hazleman B. Why is a frozen shoulder frozen? *Br J Rheumatol.* Apr 1990;29(2):130.
15. Lundberg BJ. The frozen shoulder. Clinical and radiographical observations. The effect of manipulation under general anesthesia. Structure and glycosaminoglycan content of the joint capsule. *Local bone metabolism*
16. Reeves B. The natural history of the frozen shoulder syndrome. *Scand J Rheumatol.* 1975;4(4):193-6.
17. Walmsley S, Rivett DA, Osmotherly PG. Adhesive capsulitis: establishing consensus on clinical identifiers for stage 1 using the DELPHI technique. *Phys Ther.* Sep 2009;89(9):906-17.
18. Ogilvie-Harris DJ, Biggs DJ, Fitsialos DP, et al. The resistant frozen shoulder. Manipulation versus arthroscopic release. *Clin Orthop Relat Res.* Oct 1995;238-48.
19. Binder AI, Bulgen DY, Hazleman BL, Roberts S. Frozen shoulder: a long-term prospective study. *Ann Rheum Dis.* Jun 1984;43(3):361-4.
20. Rizk TE, Pinals RS. Frozen shoulder. *Semin Arthritis Rheum.* May 1982;11(4):440-52.
21. Sano H, Hatori M, Mineta M, et al. Tumors masked as frozen shoulders: A retrospective analysis. *J Shoulder Elbow Surg.* Jun 30 2009
22. Lequesne M, Dang N, Bensasson M, et al. Increased association of diabetes mellitus with capsulitis of the shoulder and shoulder-hand syndrome. *Scand J Rheumatol.* 1977;6(1):53-6.
23. Binder AI, Bulgen DY, Hazleman BL, Tudor J, Wraight P. Frozen shoulder: an arthrographic and radionuclear scan assessment. *Ann Rheum Dis.* Jun 1984;43(3):365-9.
24. Mao CY, Jaw WC, Cheng HC. Frozen shoulder: correlation between the response to physical therapy and follow-up shoulder arthrography. *Arch Phys Med Rehabil.* Aug 1997;78(8):857-9.
25. Clunie G, Bomanji J, Ell PJ. Technetium-99m-MDP patterns in patients with painful shoulder lesions. *J Nucl Med.* Sep 1997;38(9):1491-5.