

Esophageal Foreign Bodies - Epidemiology and Management Aspects - A two years retrospective study in tertiary health care center

ANEES UR REHMAN. SHAHZAD HUSSAIN QADREE, SALAHU DIN ARBI

ABSTRACT

Objective: To review our experience with esophageal foreign bodies removal in tertiary caring health center during consecutive two years. Epidemiological aspects as well as efficacy of rigid esophagoscopy in removing of FBs was assessed.

Patients and methods: It is retrospective descriptive study. Data of consecutive one hundred and sixty patients was collected from admission record of two years from January 2008 to December 2009. Age, sex, time between ingestion and Endoscopy, nature and type of FBS, site of impaction and postoperative complications were noted. Carl stortz's rigid esophagoscopy was used for removal of FBs under general anesthesia. Analysis of data was performed manually as well as with the help of SPSS data manager

Results: One hundred and thirty patients were male 81.25% and thirty were female 18.75%. Age ranged from one year to seventy five years mean age being 5 years. Coins ingestion was the most common type of FBs, present in one hundred and thirty two 82.50% cases. Other FBs found included, pieces of bones and meat 15 dentures 6, nails and metallic wires 5 and fish thorn were found in four patients. Average time between ingestion and endoscopy was twelve hours. One hundred and twenty five 78.12% FBs were impacted at upper third, twenty five 15.62% at mid third level while remaining twelve 7.05% were removed from lower third portion of esophagus. Post operative complications took placed in three patients.

Key words: Esophageal foreign body, Children, Rigid Endoscope, management.

INTRODUCTION

In normal circumstances, deglutition process is efficient in propulsion of masticated food from oropharynx to hypo pharynx to esophagus and then into stomach so smoothly that even when we are talking and studying simultaneously masticated food bolus is directed into esophageal lumen, where esophageal peristaltic movements push it into stomach¹. How ever in children, old people or in mentally ill patients unintentionally ingested objects may be swallowed which may pass through gastrointestinal tract or may become impacted in esophagus or any where in the gastrointestinal tract². Virtually any object which is small enough to pass through the pharynx may be swallowed. Radio logically All impacted bodies in esophageal lumen may be divided in to radio-opaque or radiolucent. Common radio-opaque FBs especially in children, include coins, small toys, pencils, pens and their tops, batteries, safety pins, needles , hairpins and in

older patients parts of dentures. Food-related items such as fish and chicken or meat bones are more often ingested by older children and adults and tend to be radiolucent³. With the increased use of coins, accidental ingestion and impaction in esophagus is also increasing, especially in children^{5,6,8,12}. The majority of ingested FBs may pass safely through the gut and be passed with faces, those that reach the stomach have an 80–90% chance of passage^{4, 5, 6} but some will cause damage to the gastrointestinal tract and become lodged⁸. Depending upon the nature of FBs and site of impaction, Patients may remain asymptomatic for variable duration but ultimately symptoms start developing. Resulting complications may even lead to life threatening complications like esophageal ulceration, strictures or even perforation, medstinitis or vassal rupture⁹.

Patients with esophageal foreign bodies require prompt diagnosis and therapy. Some time highest degree of suspicion is needed in diagnosis especially when patients consult late. The first task is to determine the type of object, the time since ingestion, the location of the object, and the likelihood of associated complications¹⁰.

Depending upon the facilities available and experience of Surgeons in different centers Different

Department of ENT, Shaikh Zayed Hospital & Medical College Rahim Yar Khan.

*Correspondence to Dr. Anees ur Rehman, Senior Registrar
Email aneesrehman99@yahoo.com. 03018675972 C/O Sajid Surgical Hospital Sheikh Zaid Hospital Road Rahimyar Khan.*

strategies are used to remove lodged foreign bodies in the esophagus Common strategies are:

1. Removal using rigid or flexible esophagoscopy,
2. Extraction using a balloon catheter under radiographic guidance,
3. Pushing of the foreign body into the stomach by using boogieing.
4. Temporization, which allows the foreign body a chance to pass into the stomach on its own if it is lodged in the distal portion of the esophagus.

The strategy used depends on the type of foreign body, the length of time it has been lodged, and the relative experience with one or more of these techniques at a particular center. The success rate for removal of foreign bodies from the esophagus is 95 to 100, regardless of the technique used^{11,12}. The best method of removal of esophageal FBs will remain controversial. Over the past decade, the flexible fiber optic esophagoscope has gained great popularity, mainly owing to its safety. However, the rigid endoscope is equally safe and the ability to perform the procedure, with a high degree of success, in a controlled environment^{12,24}. The most commonly used method in our hospital for removal of esophageal foreign bodies is rigid esophagoscopy under general anesthesia. Its wide lumen is of great help in manipulating, grasping and removing most of the foreign bodies impacted anywhere in the esophageal lumen.

MATERIALS AND METHODS

This retrospective study was done on One hundred and sixty patients with a history of ingested foreign body were admitted and treated in our Department between January 2008 to December 2009; History of ingestion with vomiting, vague sensation of foreign body and odynophagia were the main diagnostic criteria, we excluded 25 children in whom at the time of admission radiographs revealed passage of coins in stomach. A lateral neck plain radiograph and a poster anterior view that included the oropharynx, neck, chest, and abdomen were made routinely before esophagoscopy examination. Data was collected from admission charts and statistical analysis was performed regarding age, sex, time between ingestion and endoscopy, level of impaction, method of extraction of foreign bodies and post operative complications were noted by manual calculations.

RESULTS

There were 130,81.25% children and 30,18.75% adults including 135 male and 25 female patients

aged 6 months to 70 years. The mean age of children was 05 years, ranging from 6 months to 5 years. The adult patients ranged from 30 to 70 years. All patients except five had a clear history and symptoms of foreign body ingestion. Three patients in our study presented with history of foreign bodies impaction, ranging from three to eight months back. Endoscopy revealed FBS impacted at growth level, biopsy proved malignant growths in two and benign growths in one patient. For patients with ingestion histories and who had negative radiological finding, computed tomography investigations were performed in two patients.

The duration from the foreign body’s ingestion to the time of endoscopic removal was as follows: less than 6 hours: 30 patients, 6-10 hours: 15 patients, 1-3 days: 110 patients and in 08 patient the duration of impaction was unknown. Foreign bodies were most commonly identified in the cervical esophagus, usually immediately below the cricopharyngeus 120 children’s. Remaining foreign bodies were as follows: In 38 patients, 30 children, 08 adults foreign bodies were lodged in the mid esophagus and in 04 patients all adults in the distal esophagus. The extraction of foreign bodies was undertaken after a fasting period of at least 5 hours, except 8 patients who underwent endoscopic procedure immediately following admission. All foreign bodies were removed under general anesthesia. A rigid esophagoscope, Karl Storz, Germany was used for removal. If the procedure lasted more than 10 minutes, methyl prednisolone was given to prevent possible soft-tissue edema. In one patient with severe respiratory symptoms, bronchoscopy was also performed and mucus plugs were aspirated. Search for preexisting changes in the esophagus, including strictures, revealed presence of esophageal growths in three patients. Coins were the most common foreign body removed from the esophagus, occurring in 130 patients, all children. In three patients double overlying coins at same level were removed. Other objects removed were bones mixed with pieces of meat, staple pin as shown in **Figure 1**, safety pins, chicken bones, and fish bone as detail wise shown in

Table 1: Follow-up is available in the majority of our patients. Within a period of 6 months to 2.5 years, there were no complications.

Level	No.	%age
Upper Third	96	60
Mid Third	42	26.25
Lower Third	22	13.75

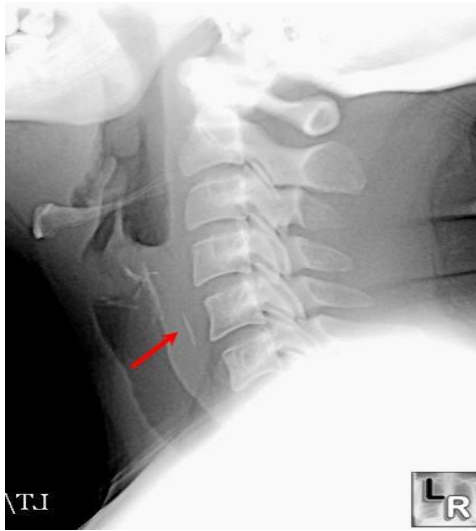

Fig 1: Radiograph of forty years old patient with staple pin in cervical part of esophagus.

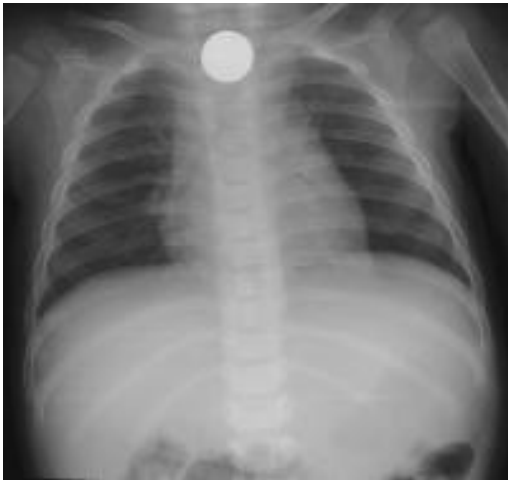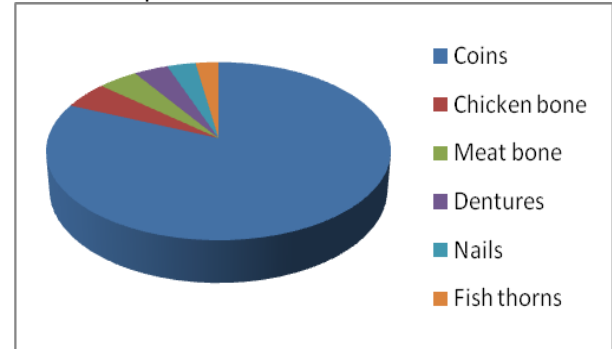


Fig. 2: Coin in a five years old child

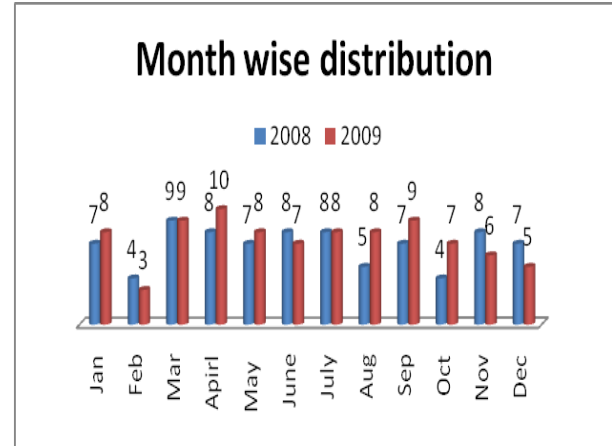
Types of FBI (n=162)

Types	Cases	Percentage
Coins	132	81.25
Chicken bone	08	05
Meat bone	07	04.37
Dentures	06	03.75
Nails and pins	05	03.12
Fish thorns	04	02.50

Level of Impaction



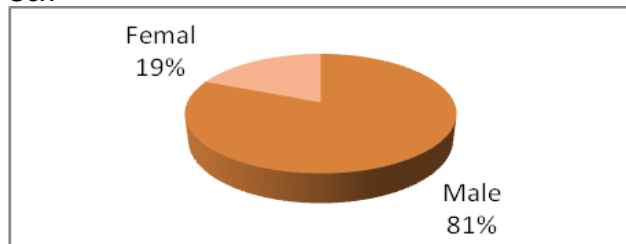
Month wise distribution



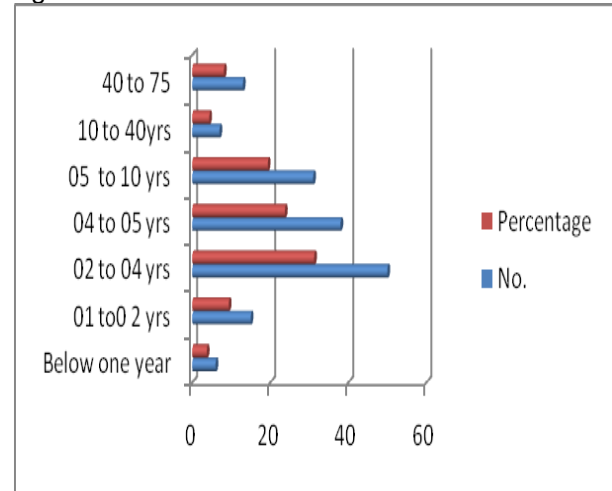
Age (n=160)

Age in Yrs	n=	%age
Below 1 year	6	3.75
01-02-	15	9.37
03-04	50	31.25
05-06	38	23.75
06-10	31	19.37
11-40	7	4.37
41-75	13	8.14

Sex



Age wise distribution



DISCUSSION

Various factors may be responsible for the swallowing of FBs. In very young children, the accident could be attributable to their natural propensity to gain knowledge by putting things into their mouth, their inability to masticate well and their inadequate control of deglutition, as well as their tendency to oral exploration and to play as they eat. Types and frequency of FBs ingestion depend on variety of psychosocial factors. The main symptoms were difficulty in swallowing, acute onset of pain, Dysphagia, choking and excessive salivation drooling. In our study, a very large number of accidents occurred in children older than three years, with no gender effect. This has been reported also in other studies^{13,14,15} and indicates the existence of a risk patterns specific for this age group. Regarding the FB type, coins were associated to both a high risk of complications and hospitalization. Nevertheless, even though the FB type is clearly associated with the onset of complications or prolonged hospitalization, what emerges from the present study is that FB characteristics play an independent role. Indeed, semi-rigid objects with higher volumes are associated with an increased risk of complications^{5,6,9}. Inorganic objects, although having a higher incidence, are less associated with complications as compared to organic objects. Nevertheless inorganic FBs most often require hospitalization. Out of the 164 patients who required hospitalization, with symptoms usually ranging from dysphagia and vomiting and pain, only 14 of them presented a complication. This is attributable to the clinical management of these patients, which associated a period of in-hospital observation to the procedure of extraction of the FB. Indeed, in our study, 92% of FBs were removed with Endoscopy, this being a definitely higher rate compared to the guidelines of the American Society for Gastrointestinal Endoscopy, where it is suggested that only 10% to 20% of foreign bodies may need to be removed endoscopically⁸. A complication rate of up to 5%, in line with the present study, is usually reported for endoscopic treatment and sometimes complications are severe, In our study, the most severe FB ingestion with complications were, one case of esophagus perforation, one case of pneumonia due to the ingestion of a coin and one case of tracheoesophageal fistula in a three years old female patient who presented after two months of impaction. This study confirms the poor consciousness among parents of the risks related to FB ingestion. Almost 50% of the accidents occurred under adult supervision and 73% of them were associated with the onset of complications. Quite

impressively, in adults and old patients, one out to five cases occurred in eating occasions, making the need of stressing the importance of an adequate preparation and mastication of food, particularly among children with esophageal abnormalities. The inadequacy of adult supervision had already been reported and constitutes a major indication toward the implementation of appropriate educational campaigns. Such intervention should be addressed also to promote the consciousness of a prompt intervention in case of an accident. Impressively, only 25% of the cases were evaluated by the parents as requiring an emergency transport to the hospital. This lack of a prompt intervention potentially leads to serious complications, as indeed observed, in case of coin ingestion.

CONCLUSION

FBs impaction in the aero digestive tract especially in pediatric age group, continues to be a common health problem. The clinical management of the patients is effective in removing the FB and in reducing the impact of the accident, in particular due the wide usage of endoscopic techniques. This is not directly impacting on the rate of hospitalization, which, in particular in view of the age of the children involved, is often seen as a precautionary measure. On the other side, prevention of FB ingestion is not addressed adequately in families, both in terms of stressing the need of active supervision of children, when playing or eating, and also in informing about the need of a prompt intervention, since the FB ingestion is often not perceived as an accident requiring an urgent and specialized treatment. High level of prevalence of this problem in our society necessitates the need the involvement of media, health workers and educationalists to make the public aware of this important problem.

REFERENCES

1. Bonadio WA, Jona JZ, Glicklich M, Cohen R. Esophageal bougienage technique for coin ingestion in children. *J Pediatr Surg* 1998;23:917-8.
2. Bailey P. Pediatric esophageal foreign body with minimal symptomatology. *Ann Emery Med* 2003;12:452-4.
3. Crysedale WS. Esophageal foreign bodies in children; 15 year review of 484 cases. *Ann Otol Rhinol laryngol* 1999;100:329-30.
4. Giordano A, Adams G, Boies L, meyerhoff W. Current management of esophageal foreign bodies. *Arch Otolaryngol* 2001;107:249-51.
5. Kraemer TA, Riding KH, Salkeld LJ. Tracheobronchial and esophageal foreign bodies in the pediatric population. *J Otolaryngol* 1998;15:355-8.

6. Jackson RM, Hawkins DB. Coins in the esophagus. what is the best management? *Int J Pediatr Otorhinolaryngol* 1998;12:127-35.
7. Nandi P, Ong GB. Foreign body in the oesophagus: review of 2394 cases. *Br J Surg* 1988;65:5-9.
8. Nahoman By, Mueller CF. Asymptomatic esophageal perforation by a coin a child. *Ann Emerg Med* 2000;13:93-5.
9. Rubin SP, Maeller DL. Removal of esophageal foreign bodies under fluoroscopic control. *Can Med Assoc J* 2003;137:125-7.
10. Spits L. Management of ingested foreign bodies in childhood. *BMJ* 2003;4:469-72.
11. Schunk JE, Corneli H, Bolte R. Pediatric coin ingestions. *Am J Dis Child* 2001;143:546-8.
15. Panda NK, Sastry KVSS, Panda NB, Reddy CE. Management of sharp esophageal foreign bodies in young children: a cause for worry. *Int J Pediatr Otorhinolaryngol* 2002; 64: 243-246.
12. Katsinelos P, Kountouras J, Paroutoglou G, Zavos C, Mimidis K, and Chatzimavrodis G. Endoscopic techniques and management of foreign body ingestion and food bolus impaction in the upper gastrointestinal tract: retrospective analysis of 139 cases. *J Clin Gastroenterol* 2006; 40: 784-789.
13. Mahafza T, Batieha A, Suboh M, Khrais T. Esophageal foreign bodies: a Jordanian experience. *Int J Pediatr Otorhinolaryngol* 2002; 64: 225-227.
14. Tsalis K, Blouhos K, Kapetanos D, Kontakiotis T, Lazaridis C. Conservative management for an esophageal perforation in a patient presented with delayed diagnosis: a case report. *Cases Journal* 2009; 2: 164.
15. McGuirt WF. Use of Foley catheter for removal of esophageal foreign bodies. A survey. *Ann Otol Rhino Laryngol* 1982; 91: 599-601.
16. Bounds BC. Endoscopic retrieval devices. *Tecniques in Gastrointestinal Endoscopy* 2006; 8:16-21.
17. Seo YS, Park J-J, Kim JH, Kim JY, Yeon JE, Kim JS, et al. Removal of press-through-packs impated in the upper esophagus an overtube. *World J*
18. Devendra I. Mehta, Magdy W. Attia et al Glucagon Use for Esophageal coin dislodgement in Children: A prospective double blind, placebo controlled trial *Academic Emergency Medicine.* 8(2):200-3, 2001 Feb
19. Stephen W.Trenker et al Esophageal Food Impaction: Treatment with Glucagon *Radiology.* . 149(2):401-3, 1983 NovMonnier P, Savary M. Foreign bodies of the esophagus: a retrospective study in 1436 adults. *Proceedings of the International Congress of Thorax Surgery, Monduzzi Editore: Bologna, 1997:197-200.*
20. Reilly J.S., Cook S.P., Stool D., Rider G. Prevention and management of aerodigestive foreign body injuries in childhood. *Pediatr Clin North Am* 1996;43:1403-1411.
21. Nandi P., Ong G.B. Foreign body in the esophagus: review of 2394 cases. *Br J Surg* 1978;65:5-9.
22. Al-Qudah A. An unusual esophageal foreign body perforation: a case report and review of the literature. *Thorac Cardiovasc Surgeon* 1991;36:102-104.
23. Elleso D.A., Rowley S.D. Esophageal perforation: its early diagnosis and treatment. *Laryngoscope* 1982;92:678-780.
24. Scher R.I., Tegtmeier C.J., Mclean W.C. Vascular injury following foreign body perforation of the esophagus. Review of the literature and report of a case. *Ann Otol Rhinol Laryngol* 1990;99:698-702.
25. Giordano A., Adams G., Boies L., Meyerhoff W. Current management of esophageal foreign bodies. *Arch Otol* 1981;107:249-251.
26. Hawkins D.B. Removal of blunt foreign bodies from the esophagus. *Ann Otol Rhinol Laryngol* 1990;99:935-940.
27. Hodge D.I.I.I., Tecklenburg F., Fleisher G. Coin ingestion: does every child need a radiograph?. *Ann Emerg Med* 1985;14:443-446.
28. Schunk J.E., Corneli H., Botle R. Pediatric coin ingestions: a prospective study of coin location and symptoms. *Am J Dis Child* 1989;143:546-548.
29. Blair S.R., Graeber G.M., Cruzzavala J.L., Gustafson R.A., Hill R.C., Warden H.E., Murray G.F. Current management of esophageal impactions. *Chest* 1993;104:1205-1209.
30. Robbins MI. Shortsleeve MJ. Treatment of acute esophageal food impaction with glucagon, an effervescent agent, and water. *AJR. American Journal of Roentgenology* 162(2):325-8, 1994 Feb