

The Role of MRI in Diagnosis of Cardiac Pathologies

MIAN WAHEED AHMAD, MALIK SAJJAD, NASIR RAZA ZAIDI

ABSTRACT

Objective: Cardiac MRI is a noninvasive diagnostic tool for heart pathologies as compare with echocardiography, angiography and cardiac CT scan

Duration: This study was conducted in the Department of Diagnostic Radiology Jinnah Hospital from 15th October to 15th December 2008.

Methods: 30 Patients clinically diagnosed for Cardiac problem were scanned after informed consent on Philips Achieva 1.5T MR system

Results: Out of the 30 patients 25 were showing (Ejection fraction) cardiac functions almost equal to the EF on echocardiography, but anatomical defect or variations are better picked on MRI (10:4). On the other hand with comparison with 64 slice cardiac CT scan, the viable walls and functions were diagnosed better with MRI however cardiac CT has edge on MRI in diagnosis of coronary problems.

Key words: Ejection fraction(EF), Magnetic resonance imaging (MRI), Computed tomography(CT), Echocardiography, Coronary Artery Disease(CAD)

INTRODUCTION

Cardiac magnetic resonance imaging (MRI) has a wide range of clinical applications. Many of these applications are commonly employed in clinical practice—for example, in the evaluation of congenital heart disease, cardiac masses, the pericardium, right ventricular dysplasia, and hibernating myocardium. Other applications, such as evaluation of myocardial perfusion and of valvular and ventricular function, are very accurately evaluated with MRI, but competing modalities such as single-photon emission computed tomography (SPECT) imaging and echocardiography are more commonly employed in clinical practice. Some applications, such as coronary artery imaging, are currently more accurately evaluated with other modalities.

Cardiac MRI is a valuable and an accurate modality used in the evaluation of structure and function of the heart. It is increasingly considered as a useful non invasive examination in management of cardiovascular conditions, a situation resulting from significant advances in MR technologies. Evaluation of congenital heart disease is an important application of Cardiac MRI since the morphological details of chambers, septum, defects and anomalous connections are depicted accurately. Additionally, flow information across valves, chambers, outflow tracts and shunts are also provided.

Its utility is further increased especially during follow up of patients after corrective surgery. Specific advantages of MRI for evaluation of women include

Department of Diagnostic Radiology, Jinnah Hospital, Lahore.

Correspondence to Dr. Mian Waheed Ahmad, Email:mian132@yahoo.com,

excellent soft tissue characterization and contrast, three dimensionality, an absolute quantification of blood flow, and overall superior temporal and spatial resolution to image vascular and myocardial abnormalities.

ADVANTAGES:

1. No Radiation
2. Independent Of Acoustic Windows
3. Can Image In Any Angle & Any plane
4. Reproducible Method Of Quantifying Ventricular Function
5. Flow Quantification
6. Does Not Require Sedation In Older Children.

PROTOCOL

1. ECG Gated phase encoded images
2. Phased Array Coil was used.
3. Image planned are following
 - Coronal (one to three images), through the middle third of the chest to provide cranial and caudal landmarks.
 - Axial (six images), planned in the coronal scout ,through the heart.
 - Oblique (six images), planned in the axial scout ,parallel to the ventricular septum.

PATIENTS AND METHODS

Cardiac MRI is a noninvasive diagnostic tool for heart pathologies as compare with echocardiography, angiography and cardiac ct scan. This study was conducted in the Department of Diagnostic Radiology Jinnah Hospital from 15th October to 11th December 2008. The patients were selected from Medical Indoor and OPD. 30 Patients clinically diagnosed for Cardiac problem were scanned after informed

consent on Philips Achieva 1.5T MR system. NPO of 2 – 4 hours followed before use of I/V contrast. Non ionic Gadolinium contrast was used where needed. 20 ml of non ionic IV contrast at 3-5 ml/sec was given and images obtained at 4-5mm interval through the chest. Images shifted to operating console for further measurements.

RESULTS

Out of the 30 patients 25 were showing (Ejection fraction) cardiac functions almost equal to the EF on echocardiography, but anatomical defect or variations are better picked on MRI (10:4). On the other hand with comparison with 64 slice cardiac CT scan, the viable walls and functions were diagnosed better with MRI however cardiac CT has edge on MRI in diagnosis of coronary problems.

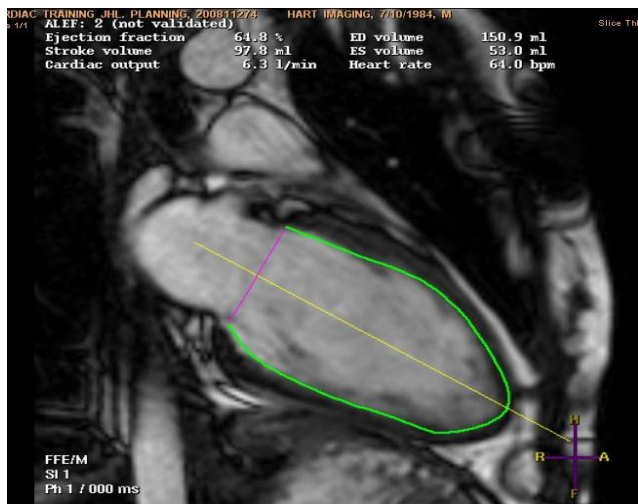


Figure 1: Measurement of the Ejection fraction in MRI. (Long axis sequences)

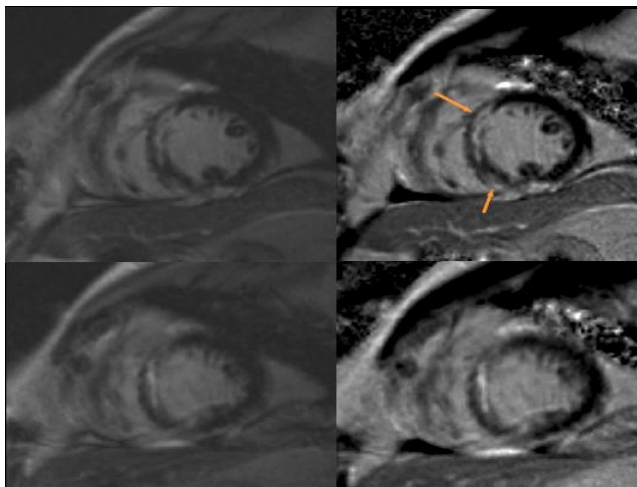


Figure 2: Acute myocardial Infarction showing delayed enhancement. (short axis sequences)

DISCUSSION

More than 400,000 women in the United States die every year from cardiovascular disease (CVD), making it the leading cause of death in the US¹.

In addition to its ability to provide anatomical and functional data, magnetic resonance (MR) can also provide tissue characterization, a technique that will help distinguish vulnerable coronary plaques from stable ones, and which is considered to be the holy grail for cardiac diagnostic imaging².

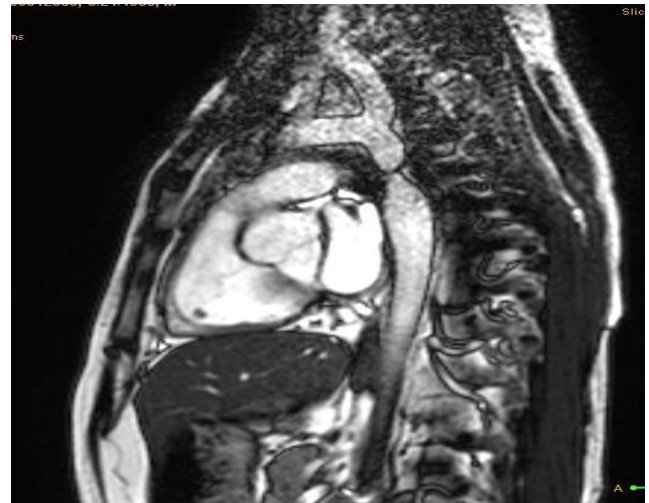


Figure 3: Aortic sequences showing co-arctation of the aorta in 26 years old man.

One of the main advantages of cardiac MRI is the lack of ionizing radiation, which is substantial with SPECT and computed tomography (CT). The strength of cardiac MRI, as compared to CT, is its superior temporal and contrast resolution. However, the spatial resolution of CT is superior. While there are competing modalities for every clinical application of cardiac MRI, there is no one modality that can provide as comprehensive an evaluation as MRI. For this reason, cardiac MRI is often known as the "one-stop shop." The challenges encountered by other noninvasive diagnostic modalities highlight cardiac MRI as an ideal non-invasive imaging modality in women. In general, non-invasive modalities face the challenge of detecting disease in women who have smaller epicardial coronary arteries, lower left ventricular mass and smaller left ventricular size than men, and greater chest³.

This capability requires improvement in a number of areas: through the currently available resolution of MR images that can be obtained through fast imaging methods, such as parallel imaging; through new data acquisition strategies that are fully under the control of the spectrometer.

The ultimate focus of MRI in this application is the development of techniques for identifying acute infarction and for differentiating viable myocardium from nonviable myocardium. The literature is filled with reports of MRI studies of acute myocardial infarction (MI). Many articles discuss the presence of increased signal intensity on T2-weighted images of regions with acute infarction; however, Filipchuk et al revealed that although sensitivity was adequate (88%), specificity was only 17% compared with controls. Myocardial thinning was the most specific finding in MI (88%), and sensitivity was only 67%. Subendocardial signal intensity changes also can be difficult to distinguish from flow-related enhancement⁴.

In a study by Rogers et al, 17 patients with reperfused MI underwent imaging with tagging and IV contrast enhancement at 1 and 7 weeks⁵.

MRI has high sensitivity in the diagnosis of constrictive pericarditis. As a finding in constrictive pericarditis, diffuse pericardial thickening of 4 mm or greater has an accuracy of 93%⁶.

Importantly, an MR perfusion imaging study by Panting et al⁷ showed that subendocardial ischemia may be responsible for chest pain in women with angina without obstructive CAD. Myocardial perfusion reserve, which can be assessed by comparing stress versus non-stress MR perfusion measurements, is inversely associated with cardiac risk factors and coronary artery calcium in asymptomatic individuals including patients with non-obstructive CAD⁸.

Previously, steady-state free-precession imaging sequences had been restricted to 1.5T due to increased static field non-homogeneities at 3T. Recent technological advances in localized shimming correct the static magnetic field and allowed these techniques to be utilized at 3T, harnessing their ability to double the overall SNR of the acquisition^{9,10}.

CONCLUSION

Cardiac MRI has become one of the most effective noninvasive imaging techniques for almost all groups of heart disease. Increased availability of dedicated cardiovascular MRI scanners with improved image quality will continue to increase the number of examinations performed with this modality.

REFERENCES

1. Rosamond W et al. Heart Disease and Stroke Statistics-2008 Update: A Report from the American Heart Association Statistics Committee and Stroke Statistics Subcommittee. *Circulation*. 2008; 117(4): 25-146.
2. Noeske R et al. Human Cardiac Imaging at 3 T using Phased Array Coils. *Magn Reson Med*. 2000; 44(6): 978-982
3. Durham N C. Cardiac MRI Provides New 3-D Images Of Beating Heart. *ScienceDaily* (Oct. 9, 2002)
4. Pamela K. Woodardl, Sanjeev Bhalla, Cylen Javidan-Nejad, et al, Cardiac MRI in the management of congenital heart disease in children, adolescents, and young adults -25 November 2008.
5. Kellman P et al. Phase-Sensitive Inversion Recovery for Detecting Myocardial Infarction using Gadolinium-Delayed Hyperenhancement. *Magn Reson Med*. 2002; 47(2): 372-383.
6. MN Sree Ram, CM Sreedhar, A Alam, IK Indrajit. The Role of cardiac MRI in congenital heart disease. 2005; 15: 2 : 239-246.
7. Panting JR et al. Abnormal Subendocardial Perfusion in Cardiac Syndrome X Detected by Cardiovascular Magnetic Resonance Imaging. *N Engl J Med*. 2002; 346(25): 1948-1953.
8. Doyle M et al. The Impact of Myocardial Flow Reserve on the Detection of Coronary Artery Disease by Perfusion Imaging Methods: an NHLBI WISE study. *J Cardiovasc Magn Reson*. 2003; 5(3): 475-485.
9. Schar M et al. Cardiac SSFP Imaging at 3 tesla. *Magn Reson Med*. 2004; 51(4): 799-806.
10. Hinton DP et al. Comparison of Cardiac MRI on 1.5 and 3.0 tesla Clinical Whole Body Systems. *Invest Radiology*. 2003; 38(7):436-442.