

Demographic, Clinical and Imaging Patterns of Proptosis

KHALID FAROOQ, TAYYABA GUL MALIK*, MUHAMMAD KHALIL*,

ABSTRACT

Objectives: To describe the Demographic, clinical and imaging patterns of Proptosis.

Study Design: Historic cohort study.

Subjects and methods: We retrospectively reviewed the clinical charts and imaging records of 87 patients with Proptosis. A detailed work up of data including age, sex, visual and orbital signs and symptoms was done. Imaging studies including orbital ultrasonography, CT scan and MRI scans were analysed. Descriptive Statistics (cross tabulation) was used for data analysis.

Results: The age ranged from 3.5 months to 85 years. (Mean 42.6 years). Male to female ratio was 1.23:1. The commonest cause of Proptosis was inflammatory diseases (50.57%), followed by tumours (42.53%) and trauma being the least common (6.9%).

Conclusion: Inflammation is the commonest cause of Proptosis. Imaging techniques are the backbone in diagnosing various causes of Proptosis.

Key words: Orbital diseases, Orbital tumours, inflammatory orbital diseases, Proptosis. Orbital trauma.

INTRODUCTION

The distance between the back of the globe and anterior end of the optic canal is 18mm. The intraorbital portion of the optic nerve is 25mm, which is 7mm larger than this distance. This helps in forward displacement of the eyeball (Proptosis) without undue stretching of the optic nerve¹. This paper describes the demographic, clinical and imaging patterns of Proptosis.

SUBJECTS AND METHODS

It was a Historic cohort study in which we retrospectively reviewed the clinical and imaging charts of patients presenting with Proptosis. Patients, whose clinical records with imaging studies were available, were included in the study, irrespective of age and sex. Eighty-seven patients were selected. Patients whose records were lacking the imaging studies or the patients where the final diagnosis was not reached, were excluded.

Clinical data included, detailed history, visual acuity, colour vision, pupillary reactions, extra ocular movements, intra ocular pressures, field of vision, measure of Proptosis with displacement of the eyeball, slit lamp examination and fundoscopy. Other specific tests were pulsations, bruit, trigeminal nerve sensations and Valsalva manoeuvre. Final diagnosis was based on clinical histopathological findings, laboratory investigations, ultrasound, CT or MRI

Department of Radiology, Ophthalmology, Lahore Medical & Dental College/Ghurki Hospital, Lahore*
Correspondence to Dr. Khalid Farooq, Associate Professor:
E-mail: kfbuzdar@gmail.com, Mob: 0321-4397531

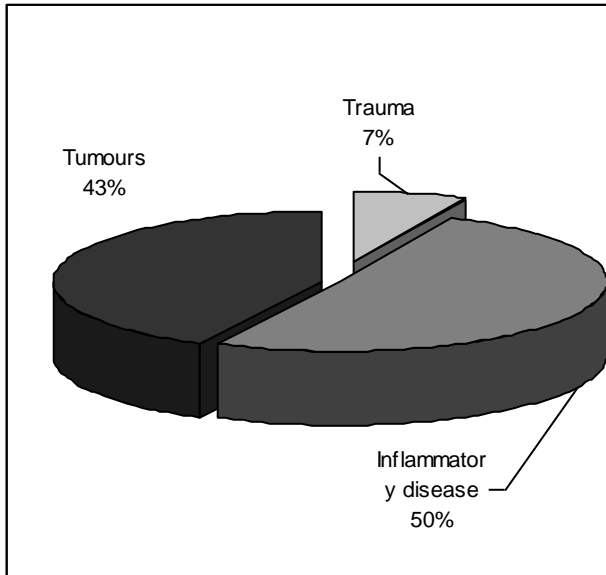
(whichever was suitable in a particular case). Ultrasound was performed with 10 MHz probe using Biovision ultrasound machine. For computerised tomography, both plain and post contrast images were acquired. Images were observed on both soft tissue and bone window settings. MRI was obtained from 0.35-T clinical imager (Opact, OPEN MRI Toshiba). T2 and T1 weighted plain and post contrast images were available. Gd-DTPA was utilized for post contrast component. Other selective investigations included T3, T4 and TSH levels. The data was analysed using Descriptive statistics.

RESULTS

Eighty-seven cases from three different centres were included in the study. Age ranged from 3.5 months to 85 years (mean 42.6). There were 48 males and 39 females (ratio being 1.23: 1). The disease presentation was unilateral in 77 patients (88.5%) and bilateral in 10 patients (11.5). eight cases out of 10 bilateral cases were diagnosed as Graves's orbitopathy. Ocular features other than Proptosis were impaired visual acuity, papilledema, ptosis, cranial nerve palsies, diplopia, peri orbital edema and congestion.

The disease pattern was divided into neoplastic, inflammatory and traumatic. In terms of percentage, 42.53% (37 patients) were diagnosed as neoplastic, 50.57% (44 patients) had inflammatory diseases and 6.9% (6 patients) had post traumatic orbital disease. (Fig 1).

Fig1: Break up of cases in terms of percentage of disease.



Inflammatory Diseases: These were further divided into following three groups:

1. Purely orbital diseases
2. Inflammation from the surrounding structures (nose, sinuses, nasopharynx and brain)
3. Inflammation secondary to systemic diseases.
4. For details, refer to table No. 1.

Table 1: Detail of inflammatory diseases causing Proptosis (n=44)

Type of inflammation	=n	%age
Purely orbital	17	38.63
Orbital cellulitis	10	
Orbital Pseudotumour	7	
From adjacent structures	18	40.9
Fungal sinusitis	7	
Nasal polyps	3	
Osteomyelitis of maxillary bone	1	
Bacterial sinusitis + dental infection	7	
Systemic diseases	9	20.45
Thyroid orbitopathy	8	
Sarcoid orbitopathy	1	

Neoplastic diseases: Neoplasia constituted the second commonest cause of Proptosis. We divided them into five categories; neurogenic, congenital, mesenchymal, epithelial and those invading from the surrounding structures/ metastasis. Tumours from adjacent structures were the commonest (37.83%) of all tumours and neurogenic tumours being the second (32.43%). For details, refer to table No. 2.

Table 2: Detail of tumours causing Proptosis (n=37)

Type of tumour	=n	%age
Neurogenic	12	32.43
Optic nerve glioma	6	
Neurofibroma	2	
Retinoblastoma	2	
Meningioma	1	
Schwannoma	1	
Congenital	2	5.4
Dermoid cysts	2	
Mesenchymal tumours	4	10.81
Lymphangioma	2	
Cavernous haemangioma	1	
Rhabdomyosarcoma	1	
Epithelial cell tumours	5	13.5
Lacrimal gland carcinoma	4	
Squamous cell carcinoma	1	
From adjacent structures/ metastasis	14	37.84
Nose and paranasal sinuses	12	
Frontal lobe tumour	1	
Leukaemia infiltrates	1	

Traumatic lesions: Trauma was the least common cause of Proptosis in our series (6.9%). For details, refer to table 3.

Table 3: Detail of traumatic lesions causing Proptosis (n=6)

Traumatic lesion	=n	%age
Carotico-cavernous fistula	4	66.67
Retro bulbar haematoma	2	33.33

DISCUSSION

The data of this study was collected from three different centres. Total number of patients was 87. There were 48 males and 39 females (1.23:1). In another local study², this ratio was found to be 2:1. Inflammatory lesions were the commonest cause of Proptosis in our study (50.57%) which is in contrast to a study by Masud MZ³ in which the commonest cause was neoplasms being 33% followed by inflammation (23%). Another local study in the paediatric age group showed the similar results⁴. Trauma accounted for 6.9% in our study, which was very close to percentage described by Masud MZ³.

If we analyse the inflammatory lesions in detail, it appears that the commonest cause of orbital inflammation was spread from the adjacent structures, which included nasal, dental, and sinus infection (40.9%). In literature⁵, this percentage is as high as 60-80%. There were only seven patients of Pseudotumour of the orbit in this study (15.9%). It is in contrast to a study by Kandpal H⁶, who describes inflammatory Pseudotumour as the second common cause of inflammation of the orbit.

For describing imaging patterns of orbital diseases, three modalities were used i.e., Ultrasonography, CT scan and MRI. Three parameters are used to diagnose a lesion with ultrasound. Topography, quantitative analysis and kinetic technique^{7,8}. Topography includes location, shape, borders and contour abnormalities. Quantitative analysis describes internal reflectivity, internal structure and sound attenuation (absorption or shadowing). Consistency of the lesion, vascularity and mobility are seen with kinetic studies⁹.

There were 37 patients with tumours in our study. These were further divided into neurogenic, congenital, mesenchymal, epithelial and congenital. Neurogenic tumours appear as solid tumours, which have high sound attenuation and presence of low amplitude internal reflection¹⁰. (Fig. 2)

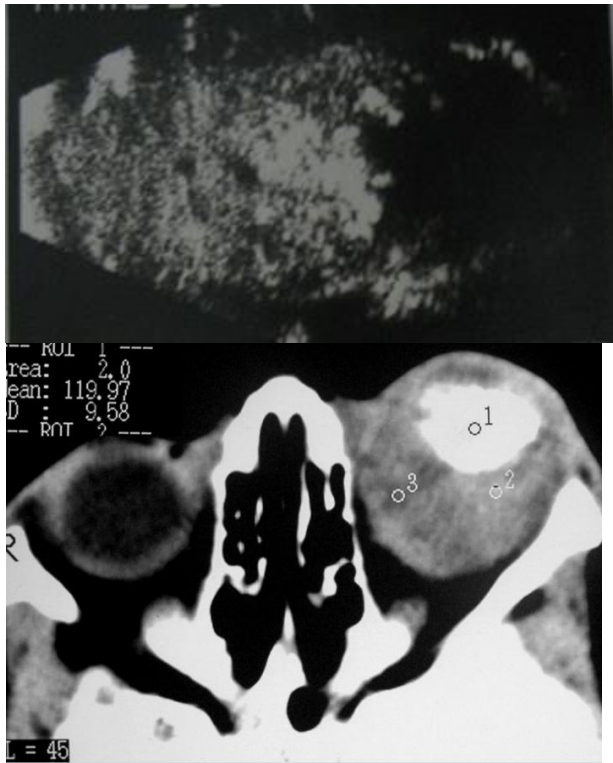

Figure 2: B-scan and CT of orbit showing calcified mass- Retinoblastoma (infiltrative tumour with areas of calcification).

Cystic tumours differ from solid tumours due to their good sound transmission with clear definition of posterior wall of lesion. Internally, they are devoid of echoes but Dermoids are exception to this rule, which may have considerable internal debris¹¹. There were four mesenchymal tumours, which included Lymphangioma, cavernous haemangioma and Rhabdomyosarcoma. Lymphangiomas and haemangioma have irregular outline and good sound

transmission. In many cases, Rhabdomyosarcoma mimic inflammatory lesions of orbit¹². Epithelial tumours, which included lacrimal gland carcinoma and squamous cell carcinoma, have ill-defined borders and poor sound transmission. In our study, there was only one patient with metastatic tumour. Ultrasonographically, metastatic tumours have infiltrative nature, medium to high reflective with a moderately irregular internal structure. Periorbital tumours extending into the orbit are usually associated with multiple bone defects. Once in side the orbit, they have low internal reflectivity and sharply demarcated from the normal orbital soft tissues.

In the present study, there were 44 cases with inflammatory diseases. It is important in this case to differentiate between thyroid orbitopathy and orbital cellulitis. In thyroid eye disease, enlarged muscles show swelling of belly of muscles and the tendons are spared^{13,14}. In orbital cellulitis and orbital Pseudotumour, whole muscle swells up. Pseudotumour remains the diagnosis of exclusion based on clinical features and response to steroids¹⁵. In case of sinusitis spreading to the orbit, it should be emphasized that normal sinuses are air filled and totally reflect the sound waves. So, no echoes are usually detected. Mucosal swelling, fluid accumulation or tissues within the sinus create abnormal echoes¹⁶.

Only six patients of orbital trauma were included in this study (4 cases of Carotico-cavernous fistula and 2 patients with retro bulbar haematoma). On ultrasound, it is difficult to differentiate between orbital haematoma and abscess¹⁷. Doppler ultrasound was performed in cases of Carotico-cavernous fistula. It showed dilated superior ophthalmic vein and turbulent flow.

Other imaging techniques like CT scan and MRI also play a very important role in finding out the cause of Proptosis. For orbital MRI scan, axial and coronal sections are adequate. Intravenous contrasts are used to differentiate between inflammation, vascular and neoplastic lesions. Gd-DTPA was used for contrast in our study. CT scan is a remarkable technique for tumours which show calcification e.g., retinoblastoma and meningioma. In inflammatory lesions, same rule applies as with the ultrasonography. Tendons are spared in thyroid orbitopathy while in orbital Pseudotumour and orbital cellulitis, inflammation extends to the tendons, lacrimal apparatus, sclera, optic nerve sheath and orbital fat¹⁸. Pseudotumours usually pose a difficulty in diagnosis. According to Dhir SP, tumours may prove to be the Pseudotumour but sometimes Pseudotumours later on turn out to be true neoplasms¹⁹.

Neuroimaging techniques are especially useful in orbital extension of Sino nasal diseases. There were 18 cases of inflammation and 13 cases of tumours, which have spread from the adjacent structures which include sinuses, nasopharynx and frontal lobe (Fig. 3).

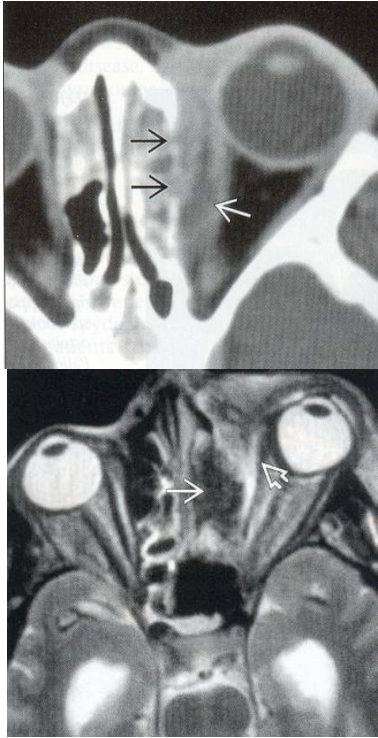


Figure 3: CT & MRI scan of orbit, axial view. Inflammatory process in left ethmoid sinus extending into the left orbit causing Proptosis.

CT scan not only shows fluid of the inflammatory process but also the region of bony defect²⁰. Although the technique of choice for Carotico-cavernous fistulas is, carotid angiography or MRA but CT scan proved valuable in our cases. There was Proptosis, swelling of extra ocular muscles, dilated superior ophthalmic vein, dilated cavernous sinus, fractures of the bones and of course the history of trauma which lead to the diagnosis of carotid cavernous sinus fistula.

MRI holds good for lesions of visual pathway and excellent for lesions of orbital apex where ultrasound fails. Most tumours are hypo intense or iso-intense on T1 weighted MRI²¹. On T2 weighted, they are slightly hyper intense and enhance with a solid pattern after contrast administration, when compared with muscle and brain (Fig. 4).

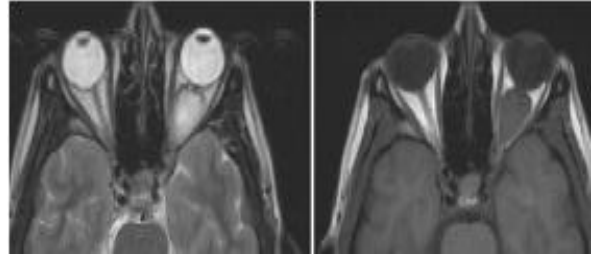


Figure 4: MRI of orbit (T2, T1 axial images) showing left optic nerve glioma.

In case of Sino nasal tumour extension into the orbit, MRI helps to establish the route of spread of tumour through foramina in the walls of the orbit²². In inflammatory mucosal diseases, there is peripheral enhancement on contrast administration. Secretions are hypo-intense on T1 weighted MRI and exhibit higher signal intensity than tumours on T2 weighted images.

CONCLUSION

In this multicentre study, Inflammation was found to be the commonest cause of Proptosis. Imaging techniques like ultrasonography, CT scan and MRI are the backbone in reaching a final diagnosis in patients presenting with Proptosis.

REFERENCES

1. Kanski JJ. Neuro-ophthalmology. In: Clinical Ophthalmology: a systematic approach. 6th Edi. Elsevier Butterworth Heinemann; 2007. P 165.
2. Khan NH, Moin M, Khan MA, et al. Unilateral Proptosis: a local experience. Biomedica 2004; 20(2):114-6.
3. Masud MZ, Babar TF, Iqbal A, et al. Proptosis: Etiology and demographic patterns. J coll Physicians Surg Pak 2006; 16(1): 38-41.
4. Qayyum S, Abid. Disease spectrum in children presenting with Proptosis. J Surg Pak 2006; 11(4): 167-9.
5. Jones DB. Microbial preseptal and orbital cellulitis. In: Duane TM (editor): Clinical Ophthalmology vol. 4. JB Lippincott; Philadelphia; 1988.
6. Kandpal H, Vashisht S, Sharma R, Seith A. Imaging spectrum of pediatric orbital pathology: A pictorial view. Indian J Ophthalmol 2006; 54: 227-36.
7. Byrne SF. Standardized echography in the differentiation of orbital lesions. Surv Ophthalmol 1984; 29: 226.
8. Byrne SF. Standardized echography of the eye and orbit. Neuroradiology 1986; 28: 618.
9. Byrne SF. Examination technique for the orbit. In: Ultrasound of the eye and orbit. Mosby year book; 1992. p 263.

10. Coleman DJ, Jack PL, Franzen LA. Neurogenic tumours of orbit. Arch Ophthalmol 1972; 88.
11. Dallow RL, Hart J. Ultrasound diagnosis of the eye and orbit. In: Albert and Jacobsen. Principles and practice of ophthalmology, vol.5. WB Saunders Co. USA; 1994. P355.
12. Rehurek J, Atrata R. Clinical diagnosis of orbital Rhabdomyosarcoma in a child. Cesk Slov Oftalmol 1997; 53: 215-19.
13. Downie AC, Howlett DC, Banerjee AK. Case of the month: A painful red eye. Br J Radiol 1995; 68: 1131-32.
14. Cherry JR. Correspondence CT scanning in orbital cellulitis. J Royal Society of Medicine 1988; 81: 124.
15. Rootman J, Nugent R. The classification and management of acute orbital Pseudotumours. Ophthalmology 1982; 89: 1040-8.
16. Byrne SF. Trauma and periorbital diseases. In: Ultrasound of the eye and orbit. Mosby year book; 1992. p 447.
17. Byrne SF. Trauma and periorbital diseases. In: Ultrasound of the eye and orbit. Mosby year book; 1992. p 433.
18. Curtin Hd: Pseudotumour imaging in ophthalmology, part 1. Radiol Clin North Am 1987; 25: 583-599.
19. Dhir SP, Zafarullah KM, Jain IS, Mohan K, Raina A. tumour masquerading as Pseudotumour of orbit. Indian J Ophthalmol 1981; 29: 23-7.
20. Mandell N, Abrahams JJ. The orbit. In: Computed Tomography and Magnetic Resonance Imaging of the whole body (vol.1) 3rd edi. Mosby year book; 1994. P 412.
21. Som PM, Shapiro MD, Biller HF, et al. Sinonasal tumours and inflammatory tissues: differentiation with mr imaging. Radiology 1988; 167(3): 803-808.
22. Raghavan P, Phillips CD. Magnetic Resonance Imaging of Sinonasal Malignancies. Top Magn Reson Imaging 2007; 18(4): 259-67.