

---

## CASE REPORT

# Cervical Rib and Complications of Thoracic Outlet Syndrome

MUHAMMAD AZEEM, MUAMMAD AHMAD GHAZI, HAFIZ MUHAMMAD ASIF MAQBOOL, AZHAR BASHIR, AMIR RIAZ BHUTTA, MUHAMMAD ARSHAD CHEEMA

### SUMMARY

Thoracic Outlet Syndrome (TOS) is an uncommon entity with a variety of arterial, venous and neurogenic symptoms. Cervical rib is one of the causes of TOS, and early diagnosis, complete investigations and appropriate management provides improved quality of life and substantially decreases the morbidity. We present a case of TOS associated with a cervical rib and a few neurogenic and vascular complications.

**Key words:** cervical rib, Thoracic outlet syndrome

---

### CASE REPORT

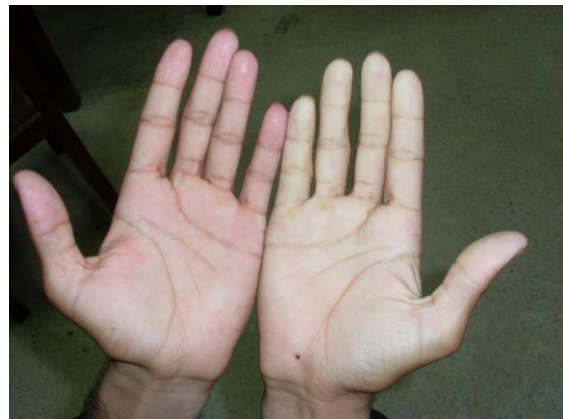A 26 year old male resident of Sheikhpura presented in out patient department with right arm pain for one month. The pain was intermittent and more marked when the patient performed manual work. Pain was more in the distal forearm and hand. It was associated with the cold sensation of the right upper extremity. Off and on he experienced pins and needles in the right lower arm, forearm and hand and developed fatigue in right upper limb shortly after doing manual work. There was no previous history of such episodes in the past. He had episodes of Raynaud's phenomenon in cold weather. The patient was non smoker and a non alcoholic.

There was no previous hospitalization and surgical intervention. No significant family history could be found. On clinical examination no visible wasting and deformity was present. There were no dilated and engorged neck veins. Burgers test was positive and Burger angle was 20 degrees. No signs of neurological insufficiency were present. Capillary refill was delayed in the right hand. On palpation there was a palpable thrill over the subclavian region with an audible bruit. Elevated arm Stress test (EAST) as well as Abduction and external rotation (AER) test were positive. Both radial and ulnar arteries were impalpable. The brachial artery flow was diminished on right side, while brachial, radial and ulnar arteries were palpable on the contra lateral side. No abnormal findings were noted on the examination of rest of the arterial system of the body.

Doppler showed Long segment occlusion of the right arm arteries by a thrombus extending from the distal brachial down to the forearm major arteries and arteries of hand. Echocardiography showed 55%

ejection fraction with no structural abnormality or clot in the heart. Color Doppler of Carotids and subclavian arteries was unremarkable bilaterally. Routine Biochemical labs were normal including the Bleeding profile.

After anti-coagulant therapy, patient was prepared for the cervical rib resection. The supraclavicular approach was used to access the cervical rib. After retracting Sternocleidomastoid muscle medially, and dividing the belly of omohyoid. Phrenic nerve was identified running over the Scalenus Anterior muscle and was saved. Brachial Plexus was identified and lateralized to avoid nerve root injury. Scalene anterior muscle was compressing the subclavian artery resulting in post-stenotic dilatation. Pleura was identified and anterior scalene muscle divided to approach the cervical rib. Cervical rib was resected. Hemostasis secured and neck closed after putting in a suction drain. The drain was removed after 24 hours. Post-operative recovery was uneventful.

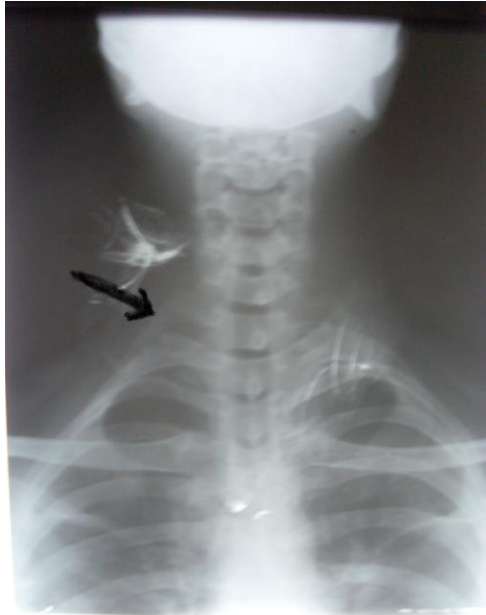

**Blanching of right hand after positive elevated arm stress test**

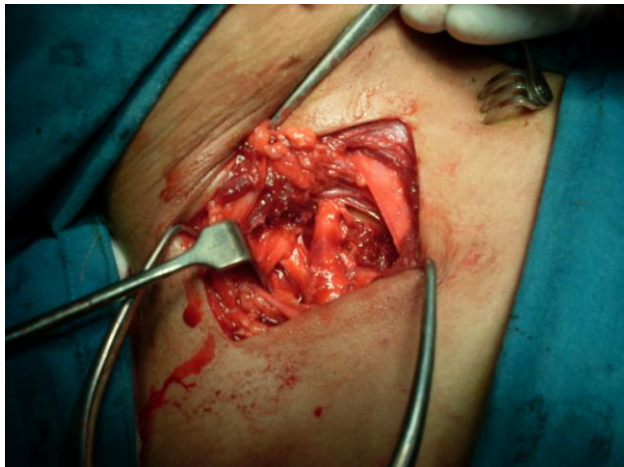
---

Department of Surgery, King Edward Medical University/Mayo Hospital, Lahore

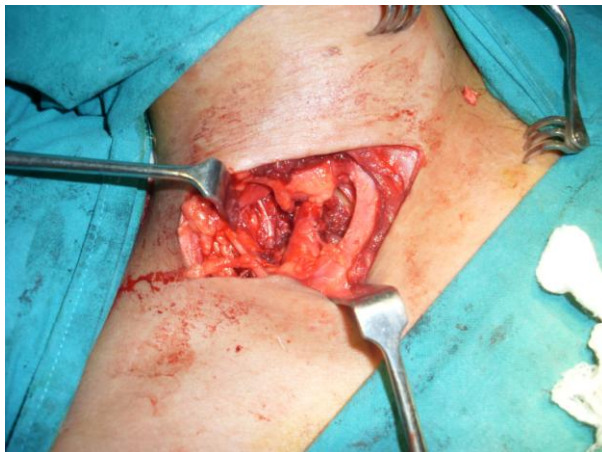Correspondence to Dr. Muhammad Ahmad Ghazi, Email: drmaghazi@hotmail.com



Arrow pointing towards a cervical rib



Exposure of cervical rib behind subclavian artery



View after rib resection

## DISCUSSION

Thoracic outlet syndrome (TOS) is classified according to the symptoms as Arterial, Neurological and Venous (Paget- Schroetter). The myriad of important structures in the thoracic outlet like, subclavian vessels, dorsal scapular and phrenic nerve, scalene muscles, brachial plexus, stellate ganglion, the thoracic duct and the cupola of lung contribute to the diversity of symptoms. Cervical rib is found in approximately 0.5% of the population and it contributes to the compressive neurovascular symptoms of the thoracic outlet.

The syndrome is caused by the combination of two factors. Firstly, anatomical narrowing; and secondly some type of trauma that triggers symptoms.

Most of the time, the symptoms are neurogenic (95%). Venous (4%-5%), and arterial (1%) symptoms are less common. <sup>4</sup> Arterial TOS is caused by emboli arising from subclavian artery stenosis or aneurysms. Symptoms are those of arterial ischemia and x-rays almost always disclose a cervical rib or anomalous first rib. Venous TOS presents with arm swelling, cyanosis, and pain due to subclavian vein obstruction, with or without thrombosis. Neurogenic TOS is due to brachial plexus compression usually from scarred scalene muscles secondary to neck trauma, whiplash injuries being the most common. Symptoms include extremity paresthesia, pain, and weakness as well as neck pain and occipital headache<sup>5</sup>. The possible sites of compression of the neurovascular bundle, which are basically three: interscalene triangle, costoclavicular space and retropectoralis minor space.

Compression in the interscalene triangle, known as **scalene syndrome**, has neurological and arterial symptoms; there are no venous symptoms, since the subclavian vein is not contained in this triangle. Costoclavicular compression syndrome can compress any bundle structure.

The need of early detection of lesions caused by emboli at an early stage is extremely important to prevent the adverse vascular events. We can manage TOS conservatively through physical therapy, rest of the activity that caused the symptoms and analgesia when the syndrome is mainly of neurological impairment. Surgical treatment is indicated in cases of failure in clinical treatment (after 6 months without improvement or symptom recurrence), uncontrolled pain and paresthesia, in addition to vascular impairment (pallor, reduced pulses, cyanosis, Raynaud's phenomenon, limb claudication or pain at rest or ulcers).

Cervical rib excision or scalenotomy is sufficient to relieve the symptoms of TOS without excision of

the first rib. There are two surgical approaches for the cervical rib resection: supraclavicular and transaxillary approach.

Studies have shown that success rates have been similar between both techniques, although the supraclavicular approach allows for a better visualization of the scalene muscle.<sup>7</sup> In addition, when the scalene muscle has any abnormality that could be responsible for the syndrome, it is possible to incise it at this moment; on the other hand, using the transaxillary approach, such procedure would be performed at a different surgical time.

Complications of the surgery include Phrenic nerve injury, Subclavian artery and vein lesions. Pneumothorax is rare if pleura is damaged inadvertently.

Venous TOS ( Paget-Schroetter syndrome ) includes subclavian vein thrombosis , venous impingement , and arterial impingement . The patients have either hypercoagulable disorders, or they may present with effort thrombosis.<sup>6</sup> Paget-Schroetter syndrome requires thrombolysis followed by surgical decompression of the subclavian vein. This gives rather better results than more conservative practices such as anticoagulation.

In one study, (Saquib et al.), it has been showed that a trial of therapeutic exercises provides relief of symptoms of Neurogenic Thoracic Outlet Syndrome in majority of patients.<sup>8</sup>

To prevent recurrence, patients must undergo first rib resection and anterior scalenectomy, as well as resection of any rudimentary or cervical ribs. In the

case of arterial TOS, the subclavian artery often requires reconstruction as well. In short, a multidisciplinary approach is the key to successfully correct TOS symptoms regardless of the type.

## REFERENCES

1. De Martino RR, Stone DH, Beck AW, Walsh DB. Thoracic Outlet Syndrome Associated With a Large Cervical Rib. *Vasc Endovascular Surg.* 2009 Jun 24.
2. Dos Reis ,Neto ETPucinelli, MLSilva , et al. Thoracic outlet syndrome (TOS) mimicking Takayasu's arteritis--case report *Acta Reumatol Port.* 2009 Jan-Mar; 34(1):96-101.
3. Davidović LB, Koncar IB, Pejkić SD, Kuzmanović IB. Arterial complications of thoracic outlet syndrome *Am Surg.* 2009 Mar; 75(3):235-9.
4. Fugate MW, Rotellini-Coltvet L, Freischlag JA. Current management of thoracic outlet syndrome. *Curr Treat Options Cardiovasc Med.* 2009 Apr;11(2):176-83.
5. Sanders RJ, Hammond SL, Rao NM. Diagnosis of thoracic outlet syndrome. *J Vasc Surg.* 2007 Sep; 46(3):601-4.
6. Arthur LG, Teich S, Hogan Met al. Pediatric thoracic outlet syndrome: a disorder with serious vascular complications. *Pediatr Surg.* 2008 Jun;43(6):1089-94.
7. Muslim M, Aamir Bilal, Abdul Baseer et al., Thoracic outlet syndrome: management and outcome. *Pak J Chest Med Apr - Jun 2008;14(2):3-6.*
8. Saquib Hanif, Noreen Tassadaq, Farooq Azam Rathore, et al. Role of therapeutic exercises in Neurogenic Thoracic Outlet Syndrome. *J Ayub Med Coll Abbottabad Oct - Dec 2007; 19(4):85-8.*