

# Laparoscopic Findings of Abdominal Tuberculosis

ZAHIRA SATTAR, MARIA MAHMOOD

## ABSTRACT

Tuberculosis is still a major health problem worldwide with about 7-10 million new cases each year and 6% of deaths all over the world. The most common extra-pulmonary manifestation of tuberculosis is Abdominal tuberculosis which poses a complex diagnostic challenge for clinicians as its presentation is often subtle. These clinically suspected cases can be correctly and readily diagnosed using the aid of diagnostic laparoscopy. The aim of our study was to highlight the use of laparoscopy in early diagnosis of abdominal tuberculosis. We conducted a cross sectional survey of 40 patients who underwent diagnostic laparoscopy with clinical suspicion of abdominal tuberculosis at Mayo Hospital Lahore from January 2007 to January 2009. The study was carried out to make an early diagnosis and to commence an early antituberculous therapy in order to decrease mortality and morbidity of the patients. In our study commonest presentations were abdominal pain, abdominal distension, weight loss, fever, loss of appetite, constipation and abdominal mass. All 40 patients underwent diagnostic laparoscopy and laparoscopic findings noted were miliary nodules, enlarged mesenteric lymph nodes, circumferential thickening of gut wall, omental thickening, fibrous adhesions, napkin ring strictures, homogenous organomegaly and ascites. Diagnosis of tuberculosis was confirmed on tissue biopsy, culture and peritoneal aspirates for culture. On the basis of these results diagnosis was confirmed in 35/38 patients with a 92% positive rate. Hence diagnostic laparoscopy can help to reach an early and accurate diagnosis by allowing the surgeon to visualize macroscopic findings and to take biopsies at the same time for confirmation of diagnosis with low morbidity and mortality.

**Key words:** abdominal Tuberculosis, Diagnostic Laparoscopy.

---

## INTRODUCTION

Worldwide, Tuberculosis is still a major health problem with 7-10 million new cases each year and 6% of deaths all over the world<sup>1</sup>. It is not only a major problem in underdeveloped countries but is now also on rise in the developed world of Europe and Asia<sup>2</sup>. The resurgence of tuberculosis has been brought on by factors such as poverty, demographic changes, an increase in immigrant and ageing population and also increasing number of other immunocompromised states such as HIV infections<sup>2</sup>.

Abdominal tuberculosis is the most common extra-pulmonary manifestation of tuberculosis caused by mycobacterium tuberculosis<sup>3</sup>. It requires a high index of suspicion by the clinician for an early and accurate diagnosis because of its non specific and variable clinical presentation<sup>4</sup>. Patients usually present with abdominal pain, abdominal distension, weight loss, fever, night sweats, anorexia, constipation, diarrhea, nausea and vomiting<sup>5,6</sup>. Clinical signs that can be elicited include fever, weight loss, pallor, ascites, abdominal tenderness<sup>7</sup>.

Abdominal tuberculosis poses a complex diagnostic challenge for clinicians as presentation is often subtle<sup>8</sup>. Therefore it can be easily overlooked with an often delay in early diagnosis<sup>9</sup>. Patients usually respond well to antituberculous therapy<sup>10</sup>. Surgery is occasionally required along with the medical therapy to treat complications as ruptured cold abscess, intestinal obstruction due to peritoneal adhesions with gut loops<sup>11</sup>. These complications can be prevented with an early accurate diagnosis thereby reducing mortality and morbidity<sup>12</sup>. These clinically suspected cases can be correctly and readily diagnosed using the aid of diagnostic laparoscopy<sup>13</sup>.

Laparoscopy can help to visualize the macroscopic features of abdominal tuberculosis such as peritoneal tubercles on visceral and parietal peritoneum, omental thickening, adhesions between bowel loops, fibrous bands, enlarged mesenteric lymph nodes, ascites, ileocecal thickening or mass, edematous hyperemic bowel loops and therefore can lead to de visu diagnosis of abdominal tuberculosis<sup>14</sup>. At the same time it allows the surgeon to take biopsies of the involved tissues to be submitted for histopathological diagnosis and culture or to take peritoneal aspirates for culture<sup>10</sup>. Laparoscopy is

---

Department of Surgery, King Edward Medical University, Mayo Hospital, Lahore  
Correspondence to Dr. Zahira Sattar,  
Email; drzahrasattar@yahoo.com

therefore safe and can help in the diagnosis of abdominal tuberculosis with a good positive diagnostic rate<sup>14</sup>. Hence, it is an effective modality for diagnosis of abdominal tuberculosis<sup>15</sup>.

The objective of our study was therefore, to stress upon the use of minimally invasive procedures to establish abdominal tuberculosis. This leads to commencement of antituberculous chemotherapy at appropriate time to prevent complications.

**MATERIAL AND METHODS**

This study was conducted on 40 patients in the surgical department of Mayo Hospital Lahore from January 2007 to January 2009. All patients presented with suspicion of abdominal tuberculosis were admitted through OPD. After the baseline investigations, chest X-rays and ultrasound abdomen were performed. Informed consent was taken for laparoscopy and to use their data in the study. 40 patients meeting the inclusion criteria and fit to undergo the procedure underwent laparoscopy. Laparoscopic findings were noted followed by taking biopsies of involved tissues and cultures of peritoneal aspirates.

**RESULTS**

In this study 40 patients were included. These patients were admitted through OPD. Patients were aged between 13-60 yrs with a mean age of 35.6 yrs. 27 of the patients were females and 13 were males with female to male ratio of 2:1.

Almost all the patients included in the study presented with 3 or more symptoms at the time of presentation. The most common amongst symptoms were abdominal pain 95% followed by loss of appetite 79% (Table 1).

Table 1: Frequency of symptoms at time of presentation

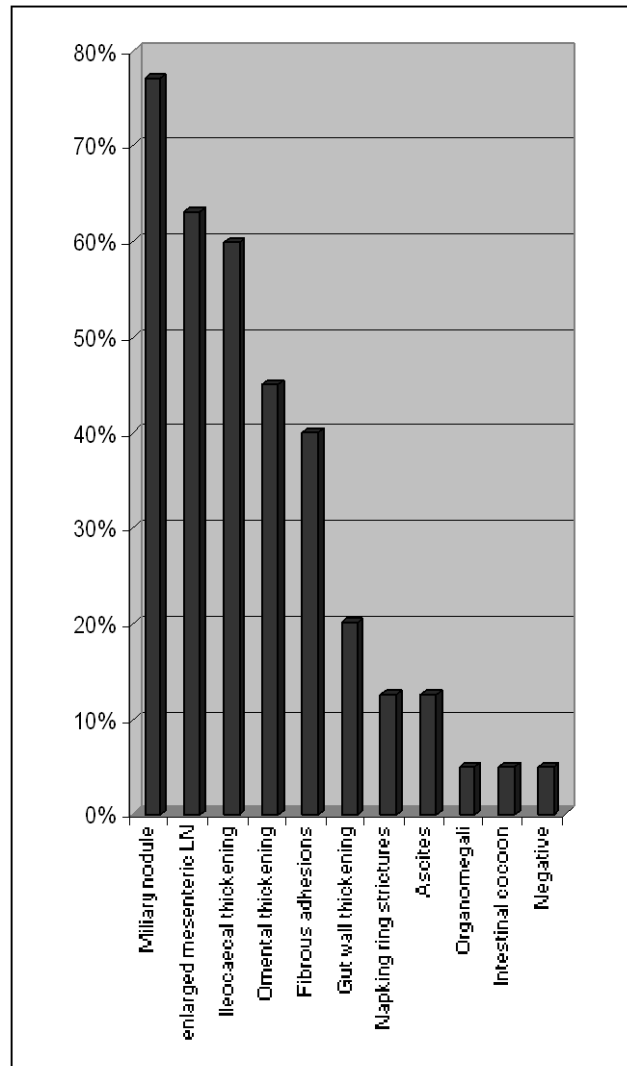
Symptoms	%age
Abdominal pain	95
Loss of appetite	79
Abdominal distension	75
Fever	72
Weight loss	70
Constipation	53
Abdominal mass	25

On complete blood examination, 34 of the patients (90%) had raised ESR whereas 30 patients (75%) had deranged TLC with lymphocytosis. About 4 patients had a borderline derangement of LFT's making a percentage of 10%. Ultrasound abdomen was performed in all the patients, with 62% were found to have features suggestive of abdominal tuberculosis like enlarged mesenteric lymph nodes,

ileocecal mass or thickening and small amount of ascites. Chest X-ray revealed evidence of pulmonary involvement in only 12 (27%) patients.

Diagnostic laparoscopy was performed in these 40 patients with commonest laparoscopic findings of miliary nodules in 31(77%) followed by enlarged mesenteric lymph nodes in 25(63%). While performing laparoscopy, peritoneal biopsies were taken which were submitted for histopathology and culture and peritoneal aspirates were taken for culture & sensitivity.

Graph: Frequency of abdominal tuberculous feature of laparoscopy



Out of total 40 patients diagnosis of abdominal tuberculosis was made in 38 patients on the basis of laparoscopic findings therefore about 95% patients were labeled to have abdominal tuberculosis on basis of laparoscopy. Diagnosis of abdominal tuberculosis

was confirmed in another 35 patients out of these 38 on basis of histopathology and culture reports with 92% positive diagnostic rate.

Thus laparoscopy provided positive diagnosis of tuberculosis in 95% patients and positive histology and culture helped confirmed the diagnosis in 92% of the labeled patients and 87.5% of the total patients. Laparoscopy under general anesthesia was successful and there was no laparoscopy related mortality.

## DISCUSSION

In our study abdominal tuberculosis was found to be more common in females with female to male ratio of 2:1 which is also indicated by the study done by Sandicki MU<sup>6</sup>, Nafeh MA<sup>10</sup>. All age groups were found to be affected by abdominal tuberculosis. Mean age of the patients was about 35.6 yrs which was similar to mean age of 36.6 yrs found in study by AIMulhim AA<sup>16</sup>.

Commonest symptoms in our study at time of presentation were abdominal pain 95%, followed by loss of appetite 79% and abdominal distension 75% also shown in the study by Safarpor F<sup>17</sup> and Chen HL<sup>9</sup>. Commonest signs were fever 65% followed by pallor similar to the study conducted by Sandicki MU<sup>6</sup> and AIMulhim AA<sup>16</sup>.

The investigations suggestive of abdominal tuberculosis found in our study were raised ESR in 90%, deranged TLC (lymphocytosis) in 75% and borderline derangement of LFTs in 10% patients whereas in a study by Manohar A<sup>18</sup> et al 58% patients showed a raised ESR. In our study chest radiograph revealed evidence of pulmonary disease in only 27% patients whereas this percentage was 40.8% in study by Manohar A<sup>18</sup>. Ultrasound abdomen showed changes like enlarged mesenteric lymph nodes and ileocecal thickening and ascites in 62% patients similar to study by Chen HL<sup>9</sup>.

All 40 patients underwent laparoscopy and most common laparoscopic findings noted were miliary nodules in 77% followed by enlarged mesenteric lymph nodes in 63% which were similar to the findings seen in study by Ibrarullah M<sup>14</sup> and Safarpor F<sup>17</sup>.

On the basis of study of 40 patients we labeled 38 (95%) patients to have abdominal tuberculosis and out of these 38 (95%) labeled patients, 35 (92%) patients were confirmed to have abdominal tuberculosis on basis of histopathology of peritoneal biopsies, cultures of peritoneal aspirates which is more than what was found to be 80% in a study by AIMulhim AA<sup>16</sup> and 82% found in the study by Safarpor F<sup>17</sup> whereas a study by Ibrarullah M<sup>14</sup> had a

positive diagnosis of abdominal tuberculosis in 87% of patients based on this modality.

## CONCLUSION

Abdominal tuberculosis can be fatal with serious complications but is a medically curable disease if diagnosed early and accurately. Tests which are associated with tuberculosis are not sensitive in detection of abdominal tuberculosis. Laparoscopy with tissue biopsy and cultures provide the most reliable, rapid and correct diagnosis of abdominal tuberculosis preventing the need of more invasive procedures and major surgery for complications. Therefore it is recommended that every patient with a high suspicion of abdominal tuberculosis should undergo diagnostic laparoscopy with tissue biopsy and culture for early diagnosis and immediate commencement of antituberculous therapy.

## REFERENCES

1. Ahmad A, Pereira SP, Steger A, Starke I. Abdominal tuberculosis: the great mimic. *Hosp Med* 2001; 62: 368-9.
2. Kehinde AO, Obaseki FA, Ishola OC, Ibrahim KD. Multidrug resistance to Mycobacterium tuberculosis in a tertiary hospital. *J Natl Med Assoc* 2007; 99: 1185-9.
3. Grau JMS, Chaves CR, Moreno JLG, Cartes JAM, Macias MS, Martinez JMA, et al. Atypical peritoneal tuberculosis: Use of laparoscopy in the diagnosis. *Rev Esp Enferm Dig* 2007; 99: 725-8.
4. Merron AR, Quraishy S. Abdominal Tuberculosis. *Pak J Chest Med* 2001;7(Suppl): 33-6.
5. Sheer TA, Coyle WJ. Gastrointestinal tuberculosis. *Curr Gastroenterol Rep* 2003; 5: 273-8.
6. Sandicki MU, Colakoglu S, Ergun Y. presentation and role of peritoneoscopy in the diagnosis of tuberculous peritonitis. *J Gastroenterol Hepatol* 1992;7(3): 298-301.
7. Poyrazoglu OK, Timurkaan M, Yalniz M, Ataseven H, Dogukan M, Bahcecioglu IH. Clinical review of 23 patients with tuberculous peritonitis: presenting features and diagnosis. *J Dig Dis* 2008; 9:170-4.
8. Koseifi S, Hoskere G, Roy TM, Byrd RP Jr, Mehta J. Peritoneal tuberculosis: modern peril for an ancient disease. *South Med J* 2009; 102: 57-9.
9. Chen HL, Wu MS, Chang WH, Shih SC, Chi H, Bair MJ. Abdominal tuberculosis in Southeastern Taiwan: 20 years of experience. *J Formos Med Assoc* 2009; 108:195-201.
10. Nafeh MA, Medhat A, Abdulhameed AG, Ahmad YA, Rashwan NM, Strickland GT. tuberculous peritonitis in Egypt: the value of laparoscopy in diagnosis. *Am J Trop med Hyg.* 1992; 47: 470-7.
11. Alrajhi AA, Halim MA, Al-Hokail A, Alrabiah F, Al-Omran K. Corticosteroid Treatment of Peritoneal Tuberculosis. *Clin Infect Dis* 1998; 27: 52-6.
12. Channa GA, Khan MA. Abdominal Tuberculosis "surgeons" perspective. *J Surg Pak* 2003; 8: 18-22.

13. Amouri A, Boudabbous M, Mnif L, Tahri N. Surrent profile of peritoneal tuberculosis: study of a Tunisian series of 42 cases and review of the literature. *Rev Med Interne* 2009;30: 215-20.
14. Ibrarullah M, Mohan A, Sarkari A, Srinivas M, Mishra A, Sundar TS. Abdominal tuberculosis: diagnosis by laparoscopy and colonoscopy. *Trop Gastroenterol* 2002; 23: 150-3.
15. Hassan I, Brilakis ES, Thompson RL, Que FG. Surgical management of abdominal tuberculosis. *J Gastrointest Surg* 2002;6: 862-7.
16. Al-Mulhim AA. Laparoscopic diagnosis of peritoneal tuberculosis. *Surg Endosc* 2004; 18: 1757-61.
17. Safarpor F, Aghajanzade M, Kohsari MRR, Hoda S, Sarshad A, Safarpor D. Role of laparoscopy in the diagnosis of abdominal tuberculosis. *Saudi J Gastroentrol* 2007; 13: 133-5.
18. Manohar A, Simjee AE, Haffejee AA. Symptoms and investigative findings in 145 patients with tuberculous peritonitis diagnosed by peritoneoscopy and biopsy over a five year period. *Gut* 1990; 31:1130-2.