

CT Guided Needle Biopsies of Intrathoracic Masses by Different Approaches

AAMIR RAHIM, MONA REHMAN, GHULAM RASOOL, MUHAMMAD FIAZ

ABSTRACT

Purpose: To report our experience with computed tomography (CT)-guided coaxial needle biopsy of intrathoracic lesions by different approaches.

Material methods:

Medical records of 100 patients who underwent CT-guided biopsy of intrathoracic lesions were evaluated retrospectively. A coaxial needle technique was used in all patients; an 18-gauge needle was used for transsternal penetration, through which a 22-gauge needle was passed to obtain fine-needle aspirates. Five patients also underwent core-needle biopsy with a coaxially introduced 20-gauge needle. Medical records were reviewed for lesion size and location, needle path, number of needle penetrations, reasons for failure, biopsy results, and complications.

Results: The transsternal approach was used in mediastinal ($n = 32$) or intrapulmonary ($n = 5$) lesions. Extrapleural access to the mediastinal lesions was achieved in all but one patient in whom the 22-gauge needle traversed the lung.

Conclusion: The CT-guided coaxial core-needle biopsy allows safe access to masses in various locations in the thorax and anteromedial lung.

Key words: Needle biopsy, CT, Intrathoracic

INTRODUCTION

Imaging-guided percutaneous core-needle biopsy has become the modality of choice for diagnosing intrathoracic masses. The parasternal, suprasternal, and transpulmonary approaches have been the traditional routes for the intrathoracic lesions. The extrapleural parasternal approach with computed tomographic (CT) or ultrasonographic (US) guidance is most appropriate for lesions that extend to the anterior chest wall lateral to the sternum.

Most intrathoracic lesions require an angled transpulmonary approach with CT guidance. The needle path traverses both the lung and the pleura, which increases the risk of pneumothorax. The transsternal approach for intrathoracic biopsy has been described in a few series of patients; the major advantage of this route is the reduction of the risks of pneumothorax and accidental injury to the internal mammary vessels. The purpose of our study was to report our experience with CT-guided coaxial needle biopsy of intrathoracic lesions by using different approaches.

MATERIALS AND METHODS

Our study was approved by our institution Ghulab Devi Trust Hospital Lahore. We retrospectively evaluated the records of 100 patients (70 men, 30 women; age range, 40-60 yrs; mean age, 55 years)

Department of Radiology, Gulab Devi Hospital, Lahore
Correspondence to Dr. Aamir Rahim, Associate Professor

who had intrathoracic masses and underwent successful ($n = 95$) or attempted ($n = 5$) CT-guided percutaneous needle biopsy at our institution from June 2007 to Dec 2007. Results of contrast material-enhanced CT were available for evaluation prior to biopsy in all cases. The coagulation parameters and platelet counts were obtained in all patients to exclude any bleeding diathesis. Written informed consent was obtained from all patients, and all biopsies were performed after the patients received conscious sedation and local anesthesia with continuous pulse oximetry and noninvasive blood pressure monitoring.

All biopsies were performed by using a helical CT scanner. Patients initially underwent imaging in the supine position with a section thickness of 5, 7, or 10mm. Non-enhanced CT was performed in 35 of the procedures, while two patients underwent contrast-enhanced CT after intravenous administration of Urografin to define the major vessels in the vicinity of the lesions.

All biopsies were performed by using a coaxial core-needle biopsy technique. A variety of guide needles were used an 18-gauge needle 18-gauge Chiba needle. The alignment of the needle was assessed with CT and adjusted if necessary. .

One to four passes were required in each patient. In five patients, additional core-needle biopsies were also performed at the recommendation of the cytopathologist examining the slides after multiple aspiration samples had failed to yield adequate

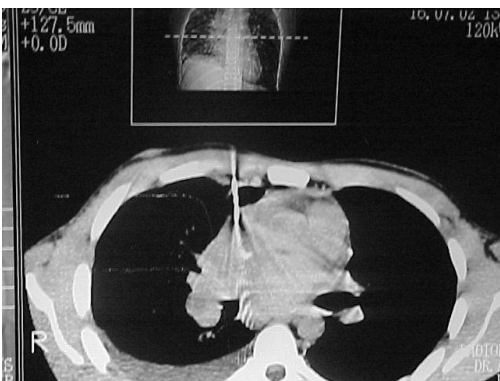
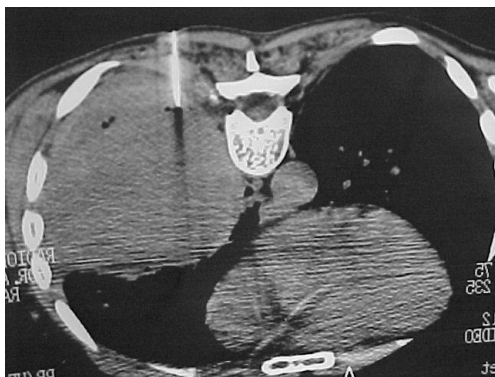
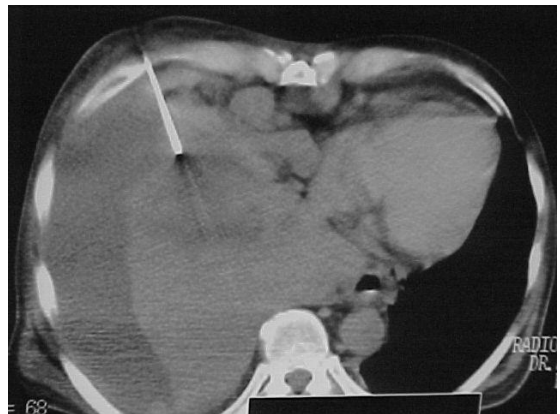
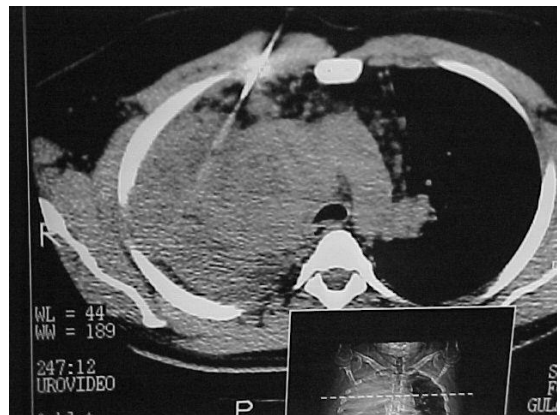
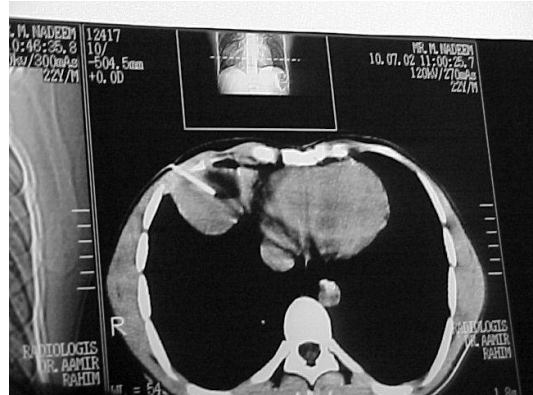
diagnostic material. Postprocedural CT scans were not routinely obtained to evaluate for complications. Expiratory chest radiographs were ordered. The patients were observed for 1–3 hours after the procedure to ensure their hemodynamic stability and to monitor their respiratory status.

RESULTS

The transsternal approach was used for biopsy in mediastinal masses or nodes (*n*=52) or in intrapulmonary lesions (*n* = 5). The intrapulmonary masses were located in the anteromedial part of the right (*n* =30) or left (*n*=14) lung, abutting and/or invading the mediastinum or retrosternal fat, soft tissue, or both. The lesions in which biopsy was performed were 1–8 cm (mean, 2.8 cm) in maximum diameter. In four patients, the lesions abutted the posterior surface of the sternum.

Non-small cell CA-252-Small cell CA-10

1. Squamous cell CA-12
2. Adeno-carcinoma-10
3. Large cell CA-6
4. Inflammatory-16
5. Non-Hodgkins lymphoma-11
6. Squamous bundle+Neurofibroma-4
7. Invasive-CA of Breast-1
8. Collapsed lung tissue-02
9. Infected Hydatid cyst-3



DISCUSSION

Percutaneous needle biopsy, initially performed with fluoroscopic guidance, is now performed with CT and US guidance, because these modalities allow precise localization and documentation of the biopsy needle and target lesion.

CT-guided parasternal and transpulmonary mediastinal biopsy also has limitations and risks. The parasternal approach is associated with a small but definite risk of hemorrhage from injury to the internal mammary videntified at CT, it may not be possible to find a safe window between the vessels and the

sternum. Hence most mediastinal tumors require an angled transpulmonary approach, with the needle traversing the lung and es but also for lesions in other mediastinal compartments and in the anterior and medial aspects of the lungs. Safe extrapleural access to middle or posterior mediastinal masses behind the great vessels in the peritracheal compartments or in the aortopulmonary window can be achieved with this technique. The transsternal approach avoids the traversal of aerated lungs, thus reducing the risk of pneumothorax. None of the patients who had pulmonary lesions and underwent transsternal biopsy in our study developed pneumothorax.

Performed contrast-enhanced CT during biopsy in all patients suggested that accurate planning of the needle trajectory requires intravenous administration of contrast material to help define the mediastinal vessels. Nonenhanced CT alone is sufficient for safe biopsy planning in most patients who have had previous diagnostic contrast-enhanced CT. The reported risk of pneumothorax with this approach ranges from 11% to 19.2% .

It is important to perform CT to check the needle direction at small increments of insertion of the guide needle.

We found that percutaneous needle insertion after the patient received local anesthesia and intravenous sedation was a well-tolerated safe procedure. No complications directly attributable to the transsternal approach were encountered in the patients in our study. Hemorrhage, a potential complication of mediastinal biopsy, can be prevented by careful planning of the biopsy needle trajectory on the basis of the location of major vessels in relation to the lesion.

The transsternal approach eliminates the risk of pneumothorax by providing an extrapleural route to the mediastinum in a majority of the patients.

We found that fine-needle aspiration biopsy provided adequate tissue for diagnosis in most patients. In conclusion, the coaxial transsternal biopsy technique allows safe access to masses in various locations within the mediastinum and anteromedial lung. This approach does not limit biopsy to the anterior mediastinum alone but allows for the sampling of lesions in the posterior mediastinum. Routine biopsy needles can be used to penetrate the sternum and gain access to the mediastinum and to

permit both multiple fine-needle aspirations and potential core sampling.

REFERENCES

1. Adler OB, Rosenberger A, Peleg H. Fine-needle aspiration biopsy of mediastinal masses: evaluation of 136 experiences. *AJR Am J Roentgenol* 1983; 140:893-896.
2. Belfiore G, Camera L, Moggio G, Vetrani A, Fraioli G, Salvatore M. Middle mediastinal lesions: preliminary experience with CT-guided fine-needle aspiration biopsy with suprasternal approach. *Radiology* 1997; 202:870-873.
3. Bressler EL, Kirkham JA. Mediastinal masses: alternative approaches to CT-guided needle biopsy. *Radiology* 1994; 191:391-396.
4. deGregorio Ariza MA, Alfonso Aguiran ER, Villavieja Atance JL, et al. Transthoracic aspiration biopsy of pulmonary and mediastinal lesions. *Eur J Radiol* 1991; 12:98-103.
5. Gupta S, Gulati M, Rajwanshi A, Gupta D, Suri S. Sonographically guided fine-needle aspiration biopsy of superior mediastinal lesions by the suprasternal route. *AJR Am J Roentgenol* 1998; 171:1303-1306. [rman SJ, Holub RV, Weisbrod GL, Chamberlain DW. Anterior mediastinal masses: utility of transthoracic needle biopsy. *Radiology* 1991; 180:167-170.
6. Rubens DJ, Strang JG, Fultz PJ, Gottlieb RH. Sonographic guidance of mediastinal biopsy: an effective alternative to CT guidance. *AJR Am J Roentgenol* 1997; 169:1605-1610.
7. Saito T, Kobayashi H, Sugama Y, Tamaki S, Kawai T, Kitamura S. Ultrasonically guided needle biopsy in the diagnosis of mediastinal masses. *Ann Rev Respir Dis* 1988; 138:679-684.
8. Weisbrod GL. Percutaneous fine-needle aspiration biopsy of the mediastinum. *Clin Chest Med* 1987; 8:27-41.
9. Wernecke K, Vassallo P, Peters PE, von Bassewitz DB. Mediastinal tumors: biopsy under US guidance. *Radiology* 1989; 172:473-476.
10. Westcott JL. Percutaneous transthoracic needle biopsy. *Radiology* 1988; 169:593-601.
11. Yang PC, Chang DB, Lee YC, Yu CJ, Kuo SH, Luh KT. Mediastinal malignancy: ultrasound guided biopsy through the supraclavicular approach. *Thorax* 1992; 47:377-380.
12. Glassberg RM, Sussman SK. Life-threatening hemorrhage due to percutaneous transthoracic intervention: importance of the internal mammary artery. *AJR Am J Roentgenol* 1990; 154:47-49.