ORIGINAL ARTICLE

Outcome of Manipulation under Anesthesia in Frozen Shoulder with and without Steroid Injection in Terms of Range of Motion

TAYYAB MAHMOOD[1], MUHAMMAD NADEEM AHSAN[2], MUHAMMAD ANAS[3]

ABSTRACT

Aim: To compare the mean difference in the range of motion between manipulation under anesthesia with and without injection of steroid in patient of frozen shoulder.
Study design: Randomized control trial
Place and duration of study: Department of Orthopedics, Bahawal Victoria Hospital, Bahawalpur from 1st May 2016 31st December 2017
Methods: A total of 156 patients, 30 to 75 years of age with frozen shoulder were included in the study. Patients with metabolic bone disease and osteoporosis were excluded. Pre-operative measurements of the range of motion of frozen shoulder (flexion, abduction, external rotation and internal rotation) were taken in all patients Then selected patients were placed randomly into two groups i.e. Group A (MUA without steroid) & Group B (MUA with steroid), by using lottery method.
Results: The mean age of women in group A was 55.65±8.13 years and in group B was 55.23±8.26 years. Out of these 156 patients, 36.54% were male and 63.46% were females with ratio of 1:1.74. Post-manipulation, the results have shown that there was significant improvement (p-value<0.05) in range of motion in group B (MUA with steroid injection) compared to group A (MUA without steroid injection).
Conclusion: There is significant improvement in range of motion after manipulation under anesthesia (MUA) with injection of steroid in patients with frozen shoulder compared to those in which MUA done without steroid injection.
Keywords: Flexion, Adhesive capsulitis, Intra-articular injection, Rehabilitation

INTRODUCTION

The human shoulder is the most mobile joint in the body. This mobility provides the upper extremity with tremendous range of motion such as adduction, abduction, flexion, extension, internal rotation, external rotation, and 360° circumduction in the sagittal plane. Furthermore, the shoulder allows for scapular protraction, retraction, elevation, and depression. This wide range of motion also makes the shoulder joint unstable[1]. This instability is compensated for by rotator cuff muscles, tendons, ligaments, and the glenoid labrum[2,3].

Frozen shoulder is a relatively common condition involving the shoulder joint, which causes pain and loss of motion in that joint, often for a substantial period of time. The shoulder joint, (the joint between the humerus and the glenoid, the socket of the scapula or wing bone) like all joints is surrounded by a capsule which is a thin but relatively strong sack of tissue which holds the normal joint fluid within the joint.[4] In addition to that function however this capsule is responsible for firstly holding the joint together so that it does not dislocate and secondly for restricting the amount of motion in the joint. If this capsule is somewhat lax there is a large range of motion available, but the joint in turn may dislocate. On the other hand if the capsule is tight the range of motion will be restricted, but the joint is very much held together and cannot dislocate.[5]

The incidence of frozen shoulder in general population is about 2%.[4,5] Individuals between 40-70 years of age are most commonly affected. It is twice common in women than in men[4]. Risk factors of frozen shoulder have been identified and are female sex, age older than 49 years, diabetes mellitus, cervical disc disease, prolonged immobilization, hyperthyroidism, stroke, myocardial infarction, Dupuytren's disease, autoimmune disease and trauma[6,7].

The exact underlying cause of frozen shoulder is unknown but, suffice to say, what happens is that the capsule of the shoulder joint becomes inflamed (that is, a true glenoid-humeral capsulitis develops). Sometimes this is thought to be as a result of trauma but more usually it comes on without injury and is probably caused by a virus (although this has not been proven). There are some factors that may support a viral causation and these include the fact that once a shoulder joint has had this condition it almost never recurs in that same joint suggesting a local immunity. On the other hand however, it can occur in the opposite shoulder joint although the incidence of that is not high[8].

There are several shoulder conditions that cause pain and reduced motion. The diagnosis of frozen shoulder should come from a provider who is well versed in differentiating various shoulder maladies. The primary symptoms of frozen shoulder are pain and stiffness. Pain may be worse at night, and is provoked by laying on the affected shoulder. As the shoulder loses its motion, even normal activities like dressing, answering the phone, or working will become difficult.[9] Frozen shoulders have three distinct stages of progression. Each stage typically takes months to progress. The normal progression of frozen shoulder through all three stages is between six months and two years. Without a purposeful effort to restore motion, the effects of a frozen shoulder may become permanent[4].

[1]Assistant Professor, [2]Senior Registrar,
[3]MO, Department of Orthopedics, B V Hospital, Bahawalpur
Correspondence to Dr. Tayyab Mahmood Email: bilal321@hotmail.com

Some people with frozen shoulder may get better over a period of 18-24 months. In other cases, symptoms can persist for several years. Studies suggest that about 50% of people with frozen shoulder continue to experience symptoms up to seven years after the condition starts. However, with appropriate treatment it is possible to shorten the period of disability.[10] The aim of treatment is to keep joint as mobile and pain free as possible while shoulder heals. The type of treatment will depend on how severe frozen shoulder is and how far it has progressed.[11]

Various treatment modalities have been proposed and are in practice for treatment of frozen shoulder. These include non-steroidal anti-inflammatory drugs, oral corticosteroids, physiotherapy, intra-articular steroid injection, distension arthrography, manipulation under anesthesia (MUA), open surgical release and arthroscopic capsular release.[4,5,11,12] The effect of each modality can be determined by using different shoulder scoring system e.g. Constant Shoulder Score (CSS), University of Pensyvania Shoulder Scale and Functional Assessment Questionnaire[10,13,14].

Most noninvasive therapeutic strategies are based on stretching or rupturing the tight capsule by manipulative physical therapy with success rate for achieving good to fair results nearing 100%[15]. The good result of physical therapy with intra-articular corticosteroid injections, with or without hydraulic distension, ranges from 44-80%.[16,17] More aggressive interventions, such as manipulation under anesthesia and arthroscopic or open release, are a popular form of therapy especially for resistant frozen shoulder. The published success rate for this therapy varies 69-97%[18,19].

Manipulation Under Anesthesia (MUA) is multidisciplinary manual therapy treatment system which is used to improve articular and soft tissue movement using specifically controlled release, myofascial manipulation, and mobilization techniques while the patient is under moderate to deep IV sedation using monitorized anesthesia care (MAC). MUA is easy, effective, inexpensive and less time consuming treatment modality[20]. Intra-articular injection of long acting local anesthetic is used to relieve post-operative pain (which is because of breaking of adhesions)[4]. Intra-articular steroids are used either alone or in combination with MUA.[21]. They are believed to provide faster improvement, but their role in management of frozen shoulder has been under discussion for a long time[22].

A study about functional outcome of frozen shoulder by Amir-us-Sqlain showed that the active range of motion after manipulation under anesthesia was abduction 151.81±13.19, forward flexion 157.19±9.12, external rotation 83.38±6.61, internal rotation to 3.56±0.51, in group-I and abduction 122.82±21.08, forward flexion 141.18±19.49, external rotation 76.76±19.76 and internal rotation 2.65±0.70 in group-II with manipulation under anesthesia and steroid injection[20].

Although MUA is common modality being used for treatment of frozen shoulder in our hospitals but there was no sufficient local literature available to indicate its effectiveness. So, we have conducted this study to establish facts about this simple and cost effective method for the treatment of frozen shoulder and also to see the outcome of steroid in frozen shoulder which has been controversial in previously conducted studies.

MATERIALS AND METHODS

This randomized control trial was conducted at Department of Orthopedics, Bahawal Victoria Hospital, Bahawalpur from 1st May 2016 31st December 2017. One hundred and fifty six cases having clinical diagnosis of frozen shoulder syndrome, frozen shoulder having range of motion between 30-75 years of age and either gender were included, whereas all cases having metabolic bone disease and osteoporosis, unfit for general anesthesia and having recently healed fractures were excluded. Pre-operative measurements of the range of motion of frozen shoulder (flexion, abduction, external rotation and internal rotation) were taken in all patients with standard goniometer by researcher himself and recorded on a specific proforma. After a patient had given informed consent for participation in the study, all selected cases were offered to pick up a slip from total mixed up slips (half-slips were contained letter ‘A’ and other half slips were contained letter ‘B’) and he/she was placed in that respective group. Base line investigations like complete blood count, random blood sugar, Urine Complete Examination, Renal functions tests and ECG (where needed) were done in every patient on admission for anesthesia purposes. Antero-posterior and lateral X-rays of the affected shoulder were done in all patients.

All patients in Group A were given general anesthesia and the frozen shoulder was manipulated in its full range of motion keeping in view the recommendations to keep short lever arm and manipulated in order of flexion, extension, abduction, external rotation and internal rotation. While all patients in Group B were undergone all above steps along with that an intra-articular steroid (40mg methyl prednisolone) was given through anterior approach (sub-acromion). After this all patients of both groups were made to undergo a regular physiotherapy session of 20 minutes daily for two weeks. The follow up examination of all patients of both groups was conducted after two weeks of the procedure by the researcher himself and range of motion of frozen shoulder (flexion, abduction, external rotation and internal rotation) was calculated with standard goniometer and was documented on specified proforma. The outcome variable i.e., range of motion (flexion, abduction, external rotation and internal rotation) were compared for any difference between both groups and student’s ‘t’ test was applied as test of significance. P-value ≤0.05 was considered as significant.

RESULTS

Age range in this study was from 30 to 75 years with mean age of 55.41±8.17 years. The mean age of patients in group A was 55.65±8.13 years and in group B was 55.23±8.26 years. Majority of the patients 72(46.15%) were between 46 to 60 years of age (Table 1). Out of these 80 patients, 57(36.54%) were male and 99(63.46%) were females with ratio of 1:1.74. The distribution of age and diabetes mellitus in both groups were shown in Figs.1-2.

Pre-manipulation range of motion (flexion, abduction, external rotation and internal rotation) has shown no significant difference between two groups (Table 2) while post-manipulation, the results have shown that there was significant improvement (p-value<0.05) in range of motion

in group B (MUA with steroid injection) compared to group A (MUA without steroid injection) (Table 3).

Table 1: Frequency of age among both groups (n=156)

Age (years)	Group A (n=78)		Group B (n=78)	
	No.	%	No.	%
30-45	19	24.36	20	25.64
46-60	37	47.44	35	44.87
61-75	22	28.20	23	24.49
Mean ± SD	55.65 ± 8.13		55.23 ± 8.26	

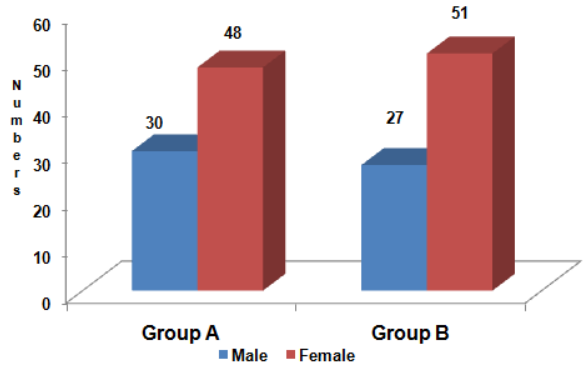

Fig. 1: Frequency of genders in both groups

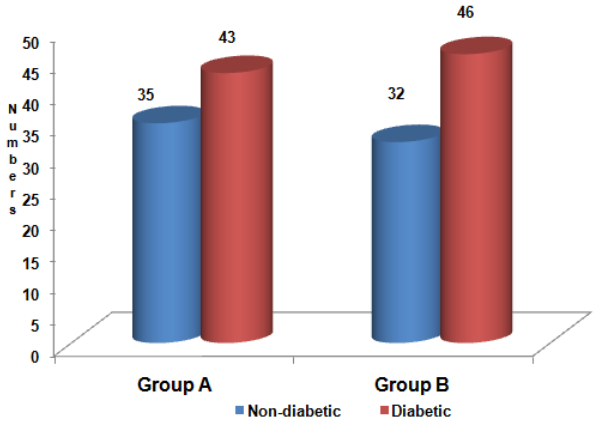

Fig. 2: Frequency of diabetes mellitus in both groups

Table 2: Pre-manipulation range of motion in both groups

Range of motion	Group A (n=78)	Group B (n=78)	P value
Flexion	83.41±22.34	83.74±21.49	0.925
Abduction	65.13±17.61	64.98±17.18	0.957
External rotation	28.33±22.19	28.02±21.79	0.93
Internal rotation	1.24±0.53	1.29±0.47	0.534

Table 3: Post-manipulation range of motion in both groups

Range of motion	Group A (n=78)	Group B (n=78)	P value
Flexion	153.41±18.20	163.8±23.2	0.0021
Abduction	137.32±15.19	161.2±18.1	0.000
External rotation	45.67±7.28	53.53±8.62	0.000
Internal rotation	3.18±0.79	3.97±1.09	0.000

DISCUSSION

Lateral epicondylitis is a common condition treated by orthopaedic surgeons. The peak incidence of lateral epicondylitis is between ages of 35–50 yrs.[1] Peak incidence in my study was between 38-42yrs. There is no difference in incidence between males and females.[2] Similar findings were noted in this study.

Lateral epicondylitis is more common in people whose activities require strong gripping or repetitive wrist movements. Dominant arm is more commonly affected.[1] In my study lateral epicondylitis was more common in manual workers who do heavy works and house wives who spent most of their time in doing house work. Among males it is more common in labourers, farmers, sweepers, plumbers etc. All these workers were included in manual workers group in my study. Lateral epicondylitis was less common in those people who do executive job and use to sit on chair most of the time and they were included in office work group in my study.

Lateral epicondylitis is a common problem with many available treatment options. When conservative treatment results in a non-satisfactory outcome, the patient is often interested in treatment options other than surgery. Steroid injections are a popular method of treating the condition but only seem to be useful in the short term and only to a small degree. Treatment with corticosteroids has a high frequency of relapse and recurrence. Study done by Poretta and Janes showed that 40% of their patients obtained complete or permanent relief of symptoms after steroid injection. Corticosteroid relieves symptoms for short period and have recurrence rate of 72%. In a recent study of Peerbooms et al[8] a positive effect of injection of PRP in the common extension origin for lateral epicondylitis was seen. This report describes the first comparison of an autologous platelet concentrate with corticosteroid injection as a treatment for lateral epicondylitis in patients who have failed non-operative treatment. It demonstrates that a single injection of concentrated autologous platelets improves pain and function more than corticosteroid injection. These improvements were sustained over time with no reported complications.[8] The use of autologous platelet rich plasma is not a new treatment.[9] The healing cascade, which is the physiological response to any injury or surgical intervention, is well documented and relies on proteins that are delivered to the healing site by platelets and white blood cells in addition to those proteins that are present in the plasma.[10,11] Successful tissue healing and regeneration requires a scaffold or matrix, undifferentiated cells and signal proteins and adhesion molecules (growth factors). It is well known that platelets affect mitogenic activity of cells like osteoblasts[12].

In one study carried out at St. Elisabeth Hospital Tilburg, Netherlands, the result shows that 24 of 49 patients (49%) in corticosteroid group and 37 of 51 patients (73%) in platelet rich plasma group were successful with the VAS Score which was significant (P<0.001), while my study shows 70.3% efficacy with PRP (P=0.045).

In my study efficacy of PRP inj. and corticosteroid inj. was compared and study showed significant better efficacy of PRP inj. Pre-injection mean pain score was almost same in both groups. 6 week after injection patients who were treated with PRP showed better improvement in there VAS pain score.

Complication rate was almost negligible in both groups with few patients showing mild cellulitis at the

injection site. There was limitation in my study as specialized equipment for extraction of platelet rich plasma was not available so ordinary blood centrifugation machine was used for platelet rich plasma extraction.

CONCLUSION

This study concludes that there is significant improvement in range of motion after manipulation under anesthesia (MUA) with injection of steroid in patients with frozen shoulder compared to those in which MUA done without steroid injection. So, we recommend that intra-articular steroid injection should be used routinely along with manipulation under anesthesia (MUA) in the treatment of frozen shoulder in order to achieve better results for this debilitating condition.

REFERENCES

1. Joost C. Peer B, Jordi S, Daniël J. Bruijn J, et al. Positive Effect of an Autologous Platelet Concentrate in Lateral Epicondylitis in a Double-Blind Randomized Controlled Trial: Platelet-Rich Plasma versus Corticosteroid Injection with a 1-Year. Am J Sports Med. 2010; 38:255-62.
2. S.Terry C, James HB. Lateral epicondylitis. In: Canale ST, Beaty JH. Campbell's operative orthopaedics. Vol III. Philadelphia: Mosby; 2008: p.2634-8.
3. Wang JH, Iosifidis MI. Biomechanical basis for tendinopathy. Clin Orthop Relat Res. 2006;443:320-32.
4. Leanne B, Elaine B, Gwendolen J, Peter , Ross D. Mobilisation with movement and exercise, corticosteroid injection, or wait and see for tennis elbow: randomized trial. Br Med J. 2006; 34:32-9
5. Nirschl R. Elbow tendinosis/tennis elbow**.** *Clin Sports Med.* 1992; 11:851-70.
6. Sclafani A, Romo T, Ukrainsky G, McCormick S, Litner J, et al. Modulation of wound response and soft tissue ingrowth in synthetic and allogeneic implants with platelet concentrate**.** *Arch Facial Plast Surg.*7:170-1.
7. Ranly D, Lohmann C, Andreacchio D, Boyan B, Schwartz Z. Platelet-rich plasma inhibits demineralized bone matrix-induced bone formation in nude mice**.** *J Bone Joint Surg [Am].* 2007; 89:139-47.
8. Peerbooms J, Sluimer J, Bruijn D, Gosens T. Positive effect of an autologous platelet concentrate in lateral epicondylitis. Am J Sport Med 2009 in press.
9. Cohen I, Diegelman R, Yager D, et al. Wound care and wound healing. In: Seymore I, Schwartz S, Shires T, Spencer F, Galloway A, eds. Principles of Surgery, 1999; 263-96.
10. Marx R, Carlson E, Eichstaedt R, et al. Platelet-rich plasma: growth factor enhancement for bone and grafts. Oral Surgery, Oral Medicine, Oral Pathology. 1998; 85(6):643-6.
11. Kirsner R, Eaglestein W. The Wound healing process. Derm Clinics. 1993;11(4):629-40.
12. Gruber P, Varga F, Fischer M, et al. Platelets stimulate proliferation of bone cells: involvement of platelet-derived growth factor, microparticles, and membranes. Clin Oral Impl Res. 2002;13:529-35.
13. O'Holleran JD, Kocher MS, Horan MP, Briggs KK, Hawkins RJ. Determinants of patient satisfaction with outcome after rotator cuff surgery. J Bone Joint Surg Am. 2005;87:121-6.
14. Constant Score: European society for surgery of shoulder and elbow (online) (SECEC/ESSSE bulletin of 2009). Available from: URL: http//www.secec.org/site/2067/default.aspx.
15. Muller LP, Rittmeister M, John J, Happ J, Kerschbaumer F. Frozen shoulder—an algoneurodystrophic process? Acta Orthop Belg. 1998;64:434-40.
16. Ritzmann P. "Frozen shoulder:" intraarticular corticosteroids lead to faster pain relief than physiotherapy [in German]. Schweiz Rundsch Med Prax. 1999;88:1369-70.
17. Hsu SY, Chan KM. Arthroscopic distension in the management of frozen shoulder. Int Orthop. 1991;15:79-83.
18. Pearsall AW, Osbahr DC, Speer KP. An arthroscopic technique for treating patients with frozen shoulder. Arthroscopy. 1999;15:2-11.
19. Dodenhoff RM, Levy O, Wilson A, Copeland SA. Manipulation under anaesthesia for primary frozen shoulder: effect on early recovery and return to activity. J Shoulder Elbow Surg. 2000;9:23-6.
20. Saqlain HA, Zubairi U, Toufiq I. Functional outcome of frozen shoulder after manipulation under anesthesia. J Pak Med Assoc. 2007;57:181-5.
21. Bukhari ZH, Zahid S. Pain management in lambago: role of acupuncture in addition to local steroid infiltration at trigger points. J Postgrad Med Inst. 2007;21:141-5.
22. Hamdan TA, Al-Essa KA. Manipulation under anesthesia for the treatment of frozen shoulder. Int Orthop. 2003;27:107-9.