

# Our Initial Experience of Modified Vaccum Assisted Closure Technique in Complicated Surgical Wounds

M .ZAHID AKBAR CHOCHAN, HASSAN M. KHAN, ZULFIQAR SALEEM, USMAN KHAN

## ABSTRACT

**Aim:** To review modified vacuum assisted closure in complicated wounds.

**Study design:** Prospective analysis

**Setting:** Department of Surgery, Avicenna Medical College

**Background:** Managing complex wounds over different areas of body, has always been challenging for surgeons for coverage and reconstruction. Salvaging severely traumatized tissue, which may include exposed tendons, bone, or vital tissue leave limited option for reconstruction. It also has increased risk of infection than other simple wounds. A plausible solution relative to other tedious options is VAC Dressing, which has promising results.

**Method:** This study is a prospective analysis of patients, presenting with complex wounds from January 2017 to January 2018, who were treated in surgical department of Avicenna Hospital Lahore. 24 patients were included in our study. Globally acclaimed apparatus for this purpose is highly expensive therefore we have devised an innovative idea to minimise the cost of this ingenious and effective method for speedy healing.

**Results:** Twenty four patients were included in the study using this modified, innovative method to achieve rapid wound healing. These included infected wounds of various intensities, ranging from infected mesh, exposed tendons and bones to contaminated wounds, Cost of our modified VAC system was less than 10 Us dollars per dressing. VAC was successful in wound management of twenty two patients while it failed in two patients.

**Conclusion:** Modified VAC is an ingenious and affordable method for patients with infected large wounds, which would otherwise require more time, money and resources. This method of VAC dressing in our study has shown good outcome even in the most complicated wounds.

**Keywords:** Vacuum assisted closure technique, complicated wounds.

---

## INTRODUCTION

Management of difficult to heal wounds has always been a cause of concern. The number of patients presenting with difficult to heal wounds has been increasing over the period of time. For the management of these wounds the conventional techniques have been in use since long, yet desired results are not achieved always. Thus a newer novel technique which might be useful in the difficult to heal wounds and delivering at par or better results as compared to the conventional techniques is the need of the hour.

The application of controlled levels of negative or sub atmospheric pressure for a prolonged period of time on a wound had clearly shown to accelerate removal of excess fluid and promote hyperaemia, which eventually promote wound healing.

Vacuum assisted closure (VAC) is a relatively new technology with applications in a variety of difficult to manage acute and chronic wounds. It is known by many pseudonyms—TNP (topical negative pressure) SPD (sub-atmospheric pressure) VST (vacuum sealing technique) and SSS (sealed surface wound suction). VAC is very effective in healing of difficult wounds but its main drawback is high cost. We modified standard VAC system to reduce its cost and then studied its effectiveness.

## METHOD

This hospital based descriptive study was carried out at Avicenna Hospital, Lahore from January 2017 to January 2018. This study included a prospective analysis of

patients, who were treated in surgical department. All consecutive patients admitted to the tertiary care Avicenna Hospital in surgery department were eligible for this study. To be included in this study, the complex wounds which were not suitable for primary closure were identified. A total of 24 patients were recruited in this study. Patients with exposed tendons, infection, and necrotic tissue were included in this study.

The exclusion criteria were diagnosed peripheral vascular disease, chronic use of steroids, coagulopathies and cancer. No patient was discriminated on basis of gender, race, socio-economic status or area of origin.

**Technique:** Modified VAC technique was developed in department of surgery, Avicenna hospital Lahore. Maintenance of a constant negative pressure on the wound is very important and so is the range of negative pressure. After careful consideration the range was kept between -120 to -180 mmHg. The time period for which the negative pressure is applied is also very important as pressure for long duration can cause necrosis and short duration would not produce desirable results. Time for application of suction was kept one hour turned on with half an hour rest in between for a period of three days before changing the dressing. The components which were used were calibrated suction machine to achieve the desired negative pressure, Silk No.1 was used to fix the suction tube embedded in the foam, Op site Dressing to seal the wound to make it air tight, Sterilised foam cut according to the dimensions of the wound with suction Drain in the substance of the foam, bactigrass placed between the wound surface and the foam.

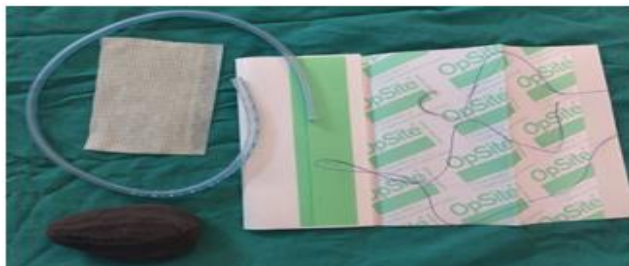Once the wound was clean and no foreign body/necrotic tissue or infective slough was present at the base of the wound, we placed bactigrass on the wound. The foam was cut according to the size and dimensions

---

*Department of Surgery, Unit 1 Avicenna Medical College, Bedian Road, Defence Phase IX, Lahore, Pakistan.*

*Correspondence to: Dr. M. Zahid Akbar, Avicenna Medical college Bedian road Lahore Defence IX Lahore.*

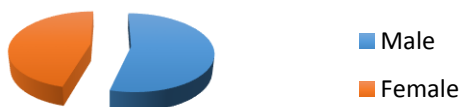keeping it within the boundaries of the wound and drain secured with silk No.1. Op site dressing was used to seal the foam over the wound. Calibrated Suction Machine was used to achieve the desired negative pressure.



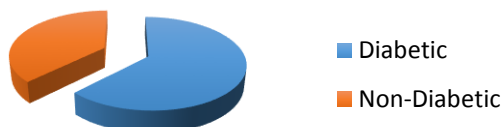## RESULTS

A total of 24 patients were included in this study that fulfilled the inclusion and exclusion criteria. There were 13 male patients and 11 female patients (Chart 1). Out of these 24 patients that presented to us over one period time, 15 patients were diagnosed with diabetes mellitus where 9 patients were non-diabetic (Chart 2). Being diabetic presented with challenge of delayed healing. There were 2 out of 24 patients who did not respond to this newly designed vacuum assistant pressure dressing as we expected (Chart 3). This is due to various different factors that we have attributed it to. One of the patients was diabetic and did not maintain strict glycemic control and the other was attributed to poor nutrition.

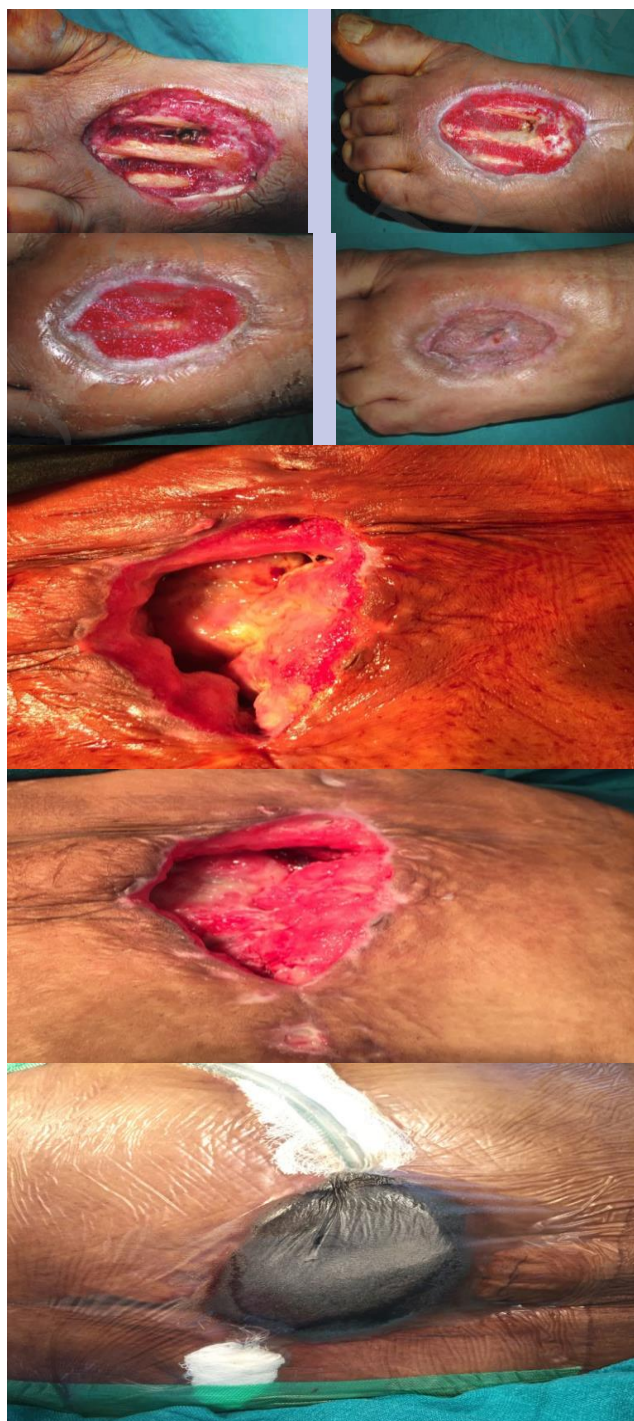
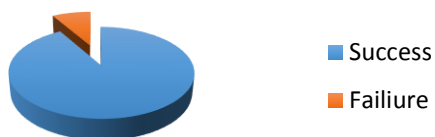
**Chart 1**



**Chart 2**



**Chart 3**



**Outcomes:** The primary outcome used were the cost, the time (in days) and percentage of granulation tissue, which was defined as a wound bed with healthy granulation tissue and without necrosis or purulent secretion. The cost was one of the driving factors of this study, as low cost treatment via VAC is necessity of under developed health system like one in Pakistan. Cost of the treatment was kept below 10\$ per patient.

The patient follow-up period started as soon as the first debridement was performed and the NPWT dressings were placed and continued until a surgery achieved

definitive wound closure. The following were secondary outcomes:

**Changes in wound bed area over time:** The wound was examined on daily basis by our in house Surgeons .The dimensions of each wound were documented using digital photography at each dressing change.

**Granulation tissue growth:** The percentage of the wound bed that was composed of granulation tissue was calculated in wound images by dividing the amount of red tissue area by the total wound area.

**Failure of intervention:** Failure of therapy was recorded if dressing could not be maintained because of persistent fluid or suction leaks or if a patient developed bleeding, invasive wound infection or sepsis, or a situation in which the dressing could worsen the patient's clinical condition, NPWT (negative pressure wound therapy) was discontinued and considered a failure.

## DISCUSSION

VAC is a newer technique in the management of variety of complex wounds which are difficult to heal and pose a challenge for coverage or reconstruction. VAC can successfully address wounds which may not be amenable to correction by other techniques like primary closure, skin grafts or loco regional flaps. Wounds like pressure sores, burns, sternotomy wounds and complex wounds with exposed tendons bones and other vital structures can be successfully addressed with this technique. A number of patent apparatuses of VAC dressings are available globally. However in our setting they are not practical owing to the scarce availability in our country and the high cost of not only the apparatus but also the dressing which needs to be changed repeatedly depending upon the nature of the wound. The few devices in Pakistan available on order are Extra care VAC Device which costs Rs.350000/- per pack which has to be repeated few times, rendering it impractical owing to the high cost in our settings. According to a publication in World Journal of Plastic Surgery the average cost amounts to USD 100 per VAC dressing. We have devised a customised apparatus by incorporating locally available items and the cost of such a device does not exceed USD10. The major limitations encountered with such innovations are leakage of negative pressure and dislodgment of the tubing which need regular daily surveillance and monitoring. The foam also has to be sterilised a day before the procedure. The availability of a dedicated calibrated suction machine also has to be assured.

## CONCLUSION

A valuable tool not only for complex wounds but a panacea for challenging conditions in wake of reconstructive options. Modified vacuum assisted is an ingenious and affordable method for patients with infected large wounds, which would otherwise require more time, money and resources.

This method of VAC dressing in our study has shown good outcome even in the most complicated wounds.

## REFERENCES

1. Morykwas MJ, Argenta LC, and Shelton-Brown EI, et al. Vacuum-assisted closure: a new method for wound control and treatment: animal studies and basic foundation. *Ann Plast Surg.* 1997;38:553–562. [PubMed]
2. Danino AM, Weber ID. [A short history of negative pressure therapy in wound healing: "to avoid the Frigidaire syndrome"]. *Ann Chir Plast Esthet.* 2007;52:624–625. [PubMed]
3. Sposato G, Molea G, Di Caprio G, et al. Ambulant vacuum-assisted closure of skin-graft dressing in the lower limbs using a portable mini-VAC device. *Br J Plast Surg.* 2001;54:235–237. [PubMed]
4. Payne C, Edwards D. Application of the single use negative pressure wound therapy device (PICO) on a heterogeneous group of surgical and traumatic wounds. *Eplasty.* 2014;14:e20. [PMC free article][PubMed]
5. Fong KD, Hu D, Eichstadt S, et al. The SNaP system: biomechanical and animal model testing of a novel ultraportable negative-pressure wound therapy system. *Plast Reconstr Surg.* 2010;125:1362–1371. [PubMed]
6. Isaac AL, Rose J, Armstrong DG. Mechanically powered negative pressure wound therapy as a bolster for skin grafting. *Plast Reconstr Surg Glob Open.* 2014;2:e103.[PMC free article] [PubMed]
7. Riot S, de Bonnecaze G, Garrido I, et al. Is the use of negative pressure wound therapy for a malignant wound legitimate in a palliative context? "The concept of NPWT ad vitam": a case series. *Palliat Med.* 2015;29:470–473.]
8. Bekara F, Herlin C, Aystaray B, et al. Suction drain-assisted split-thickness skin grafting: a simple procedure to improve skin graft take. *Plast Reconstr Surg.* 2015;135:240e–241e. [PubMed]
9. Dorafshar AH, Agarwal S, Franczyk M, et al. Low-pressure negative-pressure wound therapy using the Pleur-evac system in hemodynamically unstable patients. *Plast Reconstr Surg.* 2010;125:179e–181e. [PubMed]
10. Traitement des plaies par pression négative (TPN), des utilisations spécifiques et limitées. Recommendations HAS Janvier 2011. Available at: [http://www.has-sante.fr/portail/upload/docs/application/pdf/2010-02/fiche\\_de\\_bon\\_usage\\_traitement\\_des\\_plaies\\_par\\_pression\\_negative.pdf](http://www.has-sante.fr/portail/upload/docs/application/pdf/2010-02/fiche_de_bon_usage_traitement_des_plaies_par_pression_negative.pdf). Accessed February 22, 2010.
11. UPDATE on Serious Complications Associated with Negative Pressure Wound Therapy Systems: FDA Safety Communication. Available at: <http://www.fda.gov/MedicalDevices/Safety/AlertsandNotices/ucm244211.htm>. Accessed February 24, 2011.
12. Kim PJ, Attinger CE, Steinberg JS, et al. The impact of negative-pressure wound therapy with instillation compared with standard negative-pressure wound therapy: a retrospective, historical, cohort, controlled study. *Plast Reconstr Surg.* 2014;133:709–716. [PubMed]
13. Dorafshar AH, Franczyk M, Gottlieb LJ, et al. A prospective randomized trial comparing subatmospheric wound therapy with a sealed gauze dressing and the standard vacuum-assisted closure device. *Ann Plast Surg.* 2012;69:79–84
14. Orgill DP, Bayer LR. Update on negative-pressure wound therapy. *Plast Reconstr Surg.* 2011;127(Suppl 1):105S–115S. [PubMed].