

Chromosomal Aberrations in a Cohort of Pakistani male patients presenting with disorder of sex development (DSD)

SADIA NEMAT¹, MUHAMMAD ASIF², FAZAL-U-REHMAN KHAN³, MUHAMMAD YAQOOB⁴, MUHAMMAD NASIR IBRAHIM⁵

ABSTRACT

Background: Ambiguous genitalia is a birth defect where the outer genitalia don't have the typical appearance of either male or a female.

Aim: To detect the chromosomal aberrations in male children presenting with disorder of sex development.

Method: Thirty patients were studied whose testis were palpable or seen in sonographical examinations. Their clinical and physical examination including hormonal assay, Ultrasonography and cytogenetic analysis was done. Peripheral blood lymphocytes were cultured followed by Giemsa staining and karyotyping.

Results: Out of 30 cases under study 22 had 46, XY DSD presented with ambiguous genitalia having micropenis, palpable gonads, scrotal rugae and bifid scrotum. While 7 had hypospadias and there was 1 patient with azospermia. Consanguinity of the parents was found in 73.3% of the cases.

Conclusion: The identification of the specific causes of male disorder of sex development is very important, as it assists in patient management and family counselling. Chromosomal analysis is absolutely necessary for appropriate clinical management.

Keywords: Male DSD, Ambiguous Genitalia, Chromosomal aberrations, Consanguinity.

INTRODUCTION

The term Ambiguous genitalia refers to birth defect where the outer genitalia don't have a typical appearance of either a male or a female. The external genitalia don't match the real internal sex of the child (Claude et al., 2002). The prevalence rate of abnormal sex development in children varies. Normal sex development in human beings is important for reproduction, psychosocial and psychosexual development (Claude et al., 2002). The prevalence rate of abnormal sex development in children varies. An incidence in child's sex being uncertain is 1 per 4500 live births (Ogilvy-Stuart and Brain, 2000). The occurrence of abnormal sex development is uncommon but this is an important disorder which presents usually at birth, but may be noted during infancy or adolescence. Although there has been much progress in diagnosis, surgical techniques, understanding the psychosocial issues and recognizing and accepting the patient's advocacy, still it is necessary that this condition is recognized early and necessary steps are taken to identify the underlying cause. Although a provisional assignment of gender is often made depending upon the appearance of external genitalia but a definite diagnosis should be completed by involving a group of experts like paediatric endocrinologist, paediatric surgeon, a geneticist, paediatric urologist, a radiologist, a pathologist and a clinical psychologist (Ogilvy-Stuart and Brain, 2004).

The evaluation of a child with ambiguous genitalia requires a thorough physical examination, previous medical record family history, chromosomal test analysis hormonal assay and radiographic findings including x-rays, pelvic and abdominal ultrasonographic findings, CT scans, genitogram, Magnetic resonance imaging (MRI), endoscopy and laparoscopy (Lambert et al., 2010; Ismail and Mezan, 2010). The main purpose of diagnosis is to determine the sex by cytogenetic methods including,

Chromosomal analysis using peripheral blood, or by molecular techniques including FISH or analysis of SRY gene with PCR. In this study, we describe the use of karyotyping to determine the true gender in a study cohort of 45 children presenting with ambiguous genitalia

MATERIALS AND METHODS

Sample Collection: After the approval of the Institutional Ethical Review Board Pakistan, a total of 30 patients under the age of 18 were enrolled for this study from the Children's Hospital and Institute of Child Health, Lahore from 1st June to 31st December 2013. The selection was based on those patients who had palpable gonads on examination or present in ultrasound findings. With informed consent of the parents 3-5ml of the blood was taken in heparinized vacutainers. The samples were kept refrigerated until further analysis.

Culture and Harvesting: In the refrigerated blood samples using aseptic conditions RPMI medium (4ml), fetal calf serum (1ml), L-Glutamine (100ul), Phytohaemagglutinin (PHA 100ul), and Penicillin streptomycin (50ul) was dispensed in each T-25 flask separately with final addition of 0.5 ml of heparinized blood. Then culture flasks were incubated at 37°C for 72 hours. The contents of the flasks were mixed thoroughly at 24 and 48 hours intervals. After final fixative step the fixed cell suspension (4ml) was placed in 20°C freezer to wait for slide preparation.

Microscopy: The sample was fixed on slides and after examining the slides by phase contrast microscope to assess cell spreading, the slides were placed in the hot air oven at 60°C overnight. Then G-banding of the slides was done by rinsing in the normal saline first and then in 70 ml of trypsin (10-60 seconds), followed by Gurr buffer solution.

Then the slides were covered with Giemsa stain working solution for 6 minutes. After that slides were washed with fresh tap water and placed to pet dry. The dried stained slides were then observed under bright field microscope for the bands. 20 metaphases from each slide were counted

*Children's Hospital and Institute of Child Health, Lahore
Correspondence to Dr. Sadia Nemat*

for chromosomal number and 15 metaphases were thoroughly analysed for identification and banding pattern of each chromosome according to the international system of Cytogenetics Nomenclature (ISCN). The focused images of the selected metaphases were captured through automated Karyotyping system which displayed metaphases on the monitor screen. After that the displayed metaphases were used to prepare the Karyotypes.

Then on the basis of Karyotype results, gender of each subject was assigned and any chromosomal defect (numerical or structural) along with translocations of the chromosome in the index case and in their parents were also reported.

RESULTS

There were thirty patients in the study over a time period from 1st June 2013 to 31 December 2013. Results show different categories of the abnormal sex development in the cases under study. Palpable gonads were found with maximum frequency of (n=26) followed by hypospadias with frequency of (n=21) (Fig. 1)

Fig. 1: Frequency of different disorders

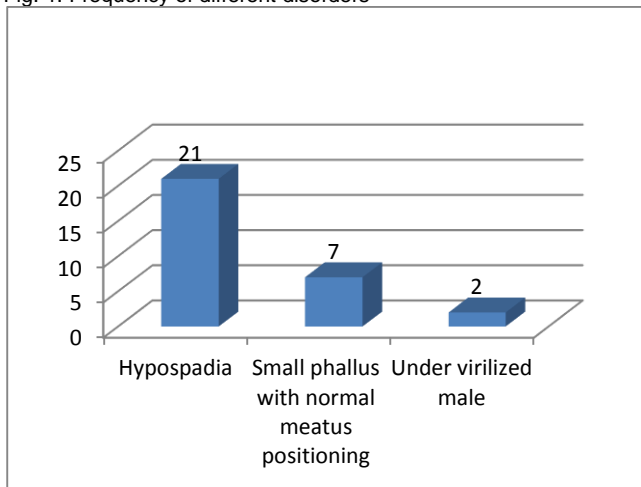


Table 1 shows the clinical features of 30 cases of male DSD. All the patients had Small phallus while additional presenting features include bifid scrotum (n=17), scrotal rugae (n=17), and hyper pigmentation with least frequency 11(36.6%). Vaginal opening was seen in one case.

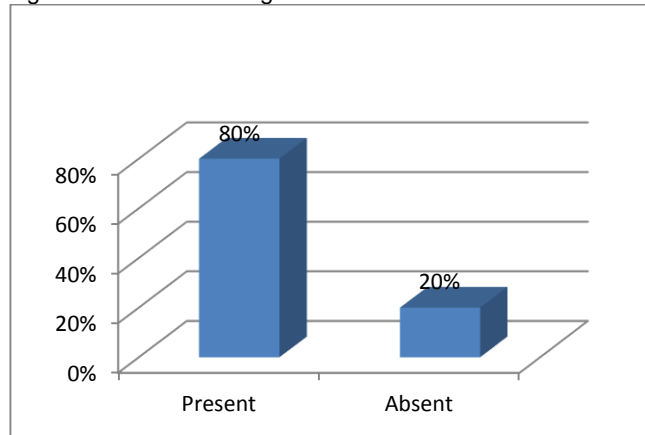
Table 1: Clinical features of male DSD cases

Clinical features	Present	Absent
Gonads Palpable	26	4
Bifid Scrotum	17	13
Small Phallus	30	0
Hyperpigmentation	11	19
Secrotalrugae	17	13
Vaginal opening	1	29

Figure 3 shows the position of external urinary meatus in 30 cases with male DSD, normal position of external urinary meatus 6(20%), hypospadias 21(70%) and epispadias 3(10%)

USG Examinations: Ultrasound examination was done for patients whose testes were not palpable 24(80%) (Fig. 2).

Fig. 2: Ultrasound findings



Hormonal analysis: Table 2 shows the biochemical studies of the population under study.

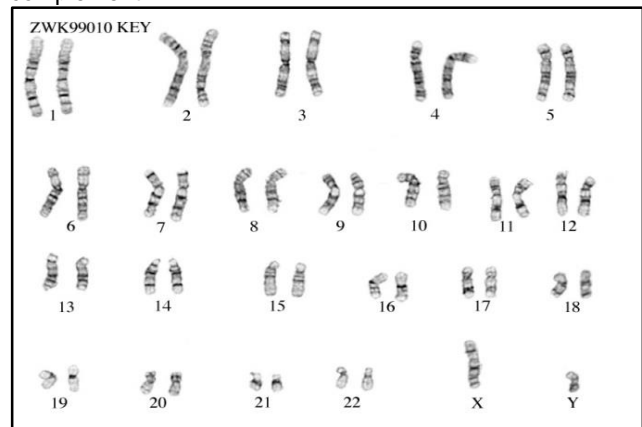
Table 2: Biochemical studies

Test	Normal	Low	Raised
Testosterone	9	21	0
LH	6	5	19
FSH	9	3	18

Consanguinity: In 23(73.3%) of the children in this study, the parents were consanguineously married.

Karyotyping: The peripheral blood cells culture revealed normal male karyotypes (46, XY) in all the 15 cells lines examined of the population under study.

Fig. 3: Karyotype of a normal male with 46XY chromosome complement



DISCUSSION

This is one of the few studies to find out the chromosomal aberrations in the male children presenting with disorder of sex development. This study clearly shows the frequency of 46, XY genotype among cases with male DSD which is 100%. Gupta and co-workers conducted a study in India in which they reported that among 60 patients in the study 43(71.6%) were male pseudo-hermaphrodite, 7(11.6%) true hermaphrodite and 10(16.6%) were with hypospadias

(Gupta et al., 2010). However the results of the present study are a very closer to another study conducted in India by Bhansali et al., (2009) which showed that the frequency of the 46, XY DSD among 95 cases with ambiguous genitalia was 47.7%. In the same study of 45 patients with 46, XY DSD, 7(15.6%) had androgen insensitivity and CAH. Six (12.2%) had 5-alpha reductase deficiency, 4(8.9%) had retractile testis and 2(4.4%) had Leutinizing hormone receptor mutation. A patient had 46, XY ovotesticular DSD. Two patients had bilateral cryptorchidism and 9(20.0%) patients had idiopathic hypospadias. Four patients had sex chromosome DSD (mixed gonadal dysgenesis) (Bhansali et al., 2009). But in present study among the clinical features of 30 cases, small phallus was found with maximum frequency of (100%) followed by palpable gonads (86%), hypospadias (70%), scrotal rugae (56.6%), bifid scrotum (56.6%), and hyperpigmentation with least frequency of 36.6%. Vaginal opening was seen in one case and that was blind vagina. Out of 30 cases were seen with ambiguous genitalia, 7 with hypospadias and 1 case was seen with azospermia. No case was seen with CAH and 5-alpha reductase as this test was not performed. A very inconsistent finding was detected by Wiersma in 2004 from India demonstrating palpable gonads in (n=34, 53%) out of 64 cases. The difference between this study and Indian study might be due to difference in geographical distribution, ethnicity and sample size.

In patients with male pseudo-hermaphroditism, affected males had clitoris like phallus, bifid scrotum, urogenital sinus and testis in inguinal canal or in labio-scrotal folds (Peterson et al.,1977). These findings are consistent with results of the present study in 17 out of 30 cases of male DSD had bifid scrotum.

Male DSD can be caused by absent mullarian regression, inadequate synthesis of testosterone hormone, inadequate synthesis of dihydrotestosterone hormone (DHT) or androgen receptor deficiency. Indications for the gender assignment according to the differential diagnosis of male pseudo-hermaphroditism are suggested (Glassberg, 1980). In our study among 30 cases of male DSD 9 patients had normal testosterone level, while 21 Patients had low levels of testosterone hormone. Follicular stimulating hormone was found with normal levels in 9 patients, low in 3 patients and raised levels were found in 18 patients of the cases.

Wiersma 2004 from India conducted a study in which he took 64 patients and reported that there are usually no pathognomonic clinical features in the children with ambiguous genitalia directing towards the real sex of the child, the true hermaphrodite present as a patient of either gender with a congenital anomaly of the genitalia. The children are likely to have a normal male phallus, bifid labio-scrotal folds, a perineal hypospadias and palpable gonads most likely to have 46, XY DSD (Wiersma 2004). In present study all the 30 patients had 46, XY DSD on karyotyping with same clinical features as observed by Wiersma.

According to the present study a total of 7 index cases showed the frequency of normal positioning of the external urinary meatus (n=7, 23.3%), frequency of

hypospadias was present in 66.6% in(n= 20) patients. In 10% of the cases (n=3) epispadias were found. To author's this information has not been published previously.

The frequency of family history in the children with ambiguous genitalia was 73.3% in 23 in the present study. This proportion is significantly higher than the prevalence of consanguineous marriages in the Punjabi population which is 46% (Yaqoob et al., 1993). A cross-sectional case finding study conducted by Abdullah and co-workers in1991 from King Khalid University Hospital, Saudi Arabia, found very consistent frequency with our frequency of consanguineous marriages among the parents of the children with ambiguous genitalia as 67.9% (Abdullah et al.,1991). Phenotype is sometimes misleading and does not give as much clear results so we performed culturing of samples followed by karyotyping (Roony 2011) to have definitive and accurate results

On karyotyping the peripheral blood cell culture of all the patients revealed normal male (46, XY) chromosomal constitution in all the 15 cells examined. The results may be 100% because of small sample size or ethnic differences from other countries. On the basis of results, it should be suggested that chromosomal analysis should be performed in every case of ambiguous genitalia to explore or identify the sex of an individual. This investigation will help in finalizing the diagnosis and genetic counselling.

CONCLUSION

Chromosomal analysis is an important investigation to establish the genetic sex family counselling of the cases with ambiguous genitalia.

Conflict of interest: None

REFERENCES

1. Abdullah, M.A., Katugampola, M., Al-Habib, Al-Jurayyan, N., Al-Samari, A., Al-Nouam, A., et al., (1991). Ambiguous genital: medical, socio-cultural religious factors affecting management in Saudi Arabia. *Ann Trop Paediatr.*, 11(4): 343.
2. AL Ogilvy-Stuart, C B Brain, (2004). Early assessment of ambiguous genitalia. *Arch Dis Child.*, 89:401-407.
3. Bhansali, Anil, D.M., Walia, Rama, DM., Singh, Ramanbir, DM., et al., (2009).
4. Claude J. Migeon, Amy B. Wisniewski, (2002). Ambiguous Genitalia WithPerineoscrotal Hypospadias in 46, XY Individuals: Long-Term Medical, Surgical, and Psychosexual Outcome. *Paediatrics*, 110(3):1-23.
5. Glassberg, K.I. (1980). Gender assingemnt in newborn male pseudohermaphrodis. *UrolClin North Am.*, 7(2): 409-21.
6. Gupta, D., Bhardwaj, M., Sharma, S., Ammini, AC., (2010). Long term psychological adjustments, satisfaction related to the gender and the family equations in disorder of sexual differentiation with male sex assignment. *PediatrSurg Int.*, 26(10): 955-8.
7. Peterson, RE., Imperato-Mc, Glinley, Gautier, Strula E., (1997). Male pseudhermaphroditism due to steroid 5-alpha reductase deficiency. *Am J Med.*, 62(2): 170-91.
8. Roony. Wiersma, R., (2004). True hermaphroditism. *PediatrSurg Int.*, 20(5): 363-8.34.
9. Yaqoob, M., Gustvason, K-H., Jail, F., Karlberg, J., IseLius, L., (1993). Early child health in Lahore, Pakistan: II. Inbreeding. *ActaPaediatr.*, 390(Suppl): 17-26.