

Effect of Incision Site on Corneal Endothelial Cell Count Changes in Cataract Surgery by Phacoemulsification

KHALID MAHMOOD*, AHMAD ZEESHAN JAMIL, TALAT MAHMOOD GONDAL, ZAHEER-UD-DIN AQIL QAZI

ABSTRACT

Objectives: A comparison was made between scleral tunnel incision and clear corneal incision for their effect on corneal endothelial cell count changes in cataract surgery by phacoemulsification.

Subjects and methods: 100 patients included in this study were selected from outpatient department of LRBT Eye Hospital and randomly divided into two groups. Group A received scleral tunnel incision and Group B received clear corneal incision. Preoperatively, specular microscopy was performed to count corneal endothelial cells. Postoperative follow up was performed at 1st day, 1 week, 6 week and 3 month.

Results: Scleral tunnel incision group resulted in $6.44\% \pm 0.62\%$ mean cell loss 3 month postoperatively. Mean cell loss 3 month postoperatively was $8.39\% \pm 0.61\%$ by clear corneal incision.

Conclusion: Compared with clear corneal incision, scleral tunnel incision was associated with lower postoperative endothelial damage.

Key words: Cataract, Endothelial cell loss, Incision, Phacoemulsification.

INTRODUCTION

Cataract is defined as any congenital or acquired opacity in the lens capsule or substance, irrespective of the effect on vision¹. Cataract is the world's leading cause of preventable blindness affecting an estimate of 20 million people. This figure is expected to increase near about 50 million by the year 2020 if no additional interventions are implemented.² 75% of the global blindness occurs in Asia and Africa. In Pakistan cataract contributes to 66.7% of the total blindness.³ Cataract surgery is the leading intraocular surgery being performed these days⁴.

Small incision suture less cataract surgery has revolutionized the surgical procedure with minimal postoperative complications, swift visual rehabilitation and mobility of patient⁵. There is a better postoperative visual acuity in patients who underwent phacoemulsification than those who underwent extra capsular cataract extraction (ECCE) at all postoperative intervals⁶. Phacoemulsification is almost universally used today⁷. Phacoemulsification by scleral tunnel incision results in less postoperative endothelial damage than that with clear corneal incision⁸.

The cornea is an excellent example of the unification of the structure and function that combine to yield an almost perfectly transparent avascular optical tissue that also serves as a barrier between

the environment and the inside of the eye. Evaluation of the corneal endothelial status before cataract surgery is important⁹. During phacoemulsification endothelial cell loss depends upon many factors¹⁰. Few of these are the size and site of incision, technique of phacoemulsification, hardness of the cataract, irrigation fluid and viscoelastic material used, and skill of the surgeon.

A healthy cornea contains about 3000 cells per square millimeter. With pathologic cellular damage or substantial reduction in cell density from a normal value between 1400 and 2500 cells/mm² to a critical value of approximately 400 to 700 cells/mm², the endothelial transport capability becomes overwhelmed, and chronic stromal edema can ensue¹¹.

The corneal specular microscope is a reflected light microscope that projects light onto the cornea thus imaging the light reflected from an optical interface of the corneal tissue, most typically the interface between the corneal endothelium and aqueous humour. Depending on the instrument used, the projected light can be in the form of a stationary slit, a moving slit, or a moving spot. The optical design can either be confocal or non confocal¹².

The primary importance in clinical specular microscopy is the light that is reflected specularly (mirror like) where the angle of reflection is equal to the angle of incidence¹³. This reflected light is captured by the clinical specular microscope and forms the endothelial image.

The Konan Noncon Robo Specular Microscope is the most automated instrument yet developed;

*Department of Ophthalmology, Avicenna Medical College, Lahore

LRBT Eye Hospital, Lahore

Correspondence to Dr. Khalid Mahmood, Associate Professor Ophthalmology Email: eyesaver66@yahoo.com

tracking the cornea and imaging the endothelium are fully automatic requiring minimal intervention by the operator. The optics of the instrument first objectively aligns itself relative to the cornea by using the Purkinje images until the proper specular reflection mode is achieved.

Purpose of this study was to compare the changes in endothelial cell count during phacoemulsification by scleral tunnel incision and clear corneal incision while keeping the other variables constant.

MATERIAL AND METHODS

The study was conducted at LRBT Eye Hospital Lahore from September 2009 to March 2010. One hundred patients having visually significant cataract (Nucleosclerosis +2/+3) were selected from out-patient department of LRBT Eye Hospital and enrolled. Patients were asked to sign the informed consent. The patients were randomly allocated in two groups by using random number tables. Group A was operated by scleral tunnel incision and group B was operated by clear corneal incision. Sociodemographic profile like name, age, gender and history of current disease with respect to symptoms, severity and duration was taken. (Table1). Examination included detailed anterior segment examination with slit lamp, visual acuity with Snellen’s chart, intraocular pressure measurement with Goldmann’s applanation tonometer and dilated fundus examination. Preoperative specular microscopy was carried out with Konan Noncon Robo specular microscope to count corneal endothelial cells. (Table No. 2).

All patients were operated upon under local anaesthesia (retro bulbar injection) by using 1:1 mixtures of 2% Lidocaine and 0.5% Bupivacaine HCL. Surgery was performed under strict aseptic measures. Scleral tunnel incision started 2 mm posterior to supro-temporal limbus. A scleral tunnel was dissected and the anterior chamber entered with a 3.2 mm angled slit knife. Clear corneal incision was also located at supro-temporal limbus. The incision entry point was 0.50 mm into clear cornea. The incision was made with a 3.2 mm angled slit knife starting at about half of corneal thickness and creating a 3.2 mm wide, 1.75 to 2.00 mm long tunnel into the clear cornea. A stab incision was made at the end of the tunnel to penetrate the anterior chamber. After an uneventful phacoemulsification, both incisions were enlarged to 5.5 mm wide and a rigid PMMA IOL was implanted in the capsular bag. Phaco power, viscoelastic, irrigation solution and intraocular lens were kept constant in all patients.

Postoperatively all patients were sent to home with a sterile eye pad on the operated eye. Next

morning pad was removed under aseptic measures and complete postoperative examination carried out. Each patient received a combination of Tobramycin 0.3% and 0.1% Dexamethasone eye drops six times per day. The medicines were tapered in 6 weeks duration. Follow up by specular microscope was carried out at 1st day, 1 week, 6 week and 3 month.

RESULTS

In this study a comparison was made between scleral tunnel incision and clear corneal incision for their effect on corneal endothelial cell count changes in cataract surgery by phacoemulsification.

In group A, mean preoperative endothelial cell count was 2695.30 cell / mm², ranging from 2215 to 2896 cell / mm², with standard deviation of 131.43 cell / mm². In group B, mean endothelial cell count was 2665.82 cell / mm², ranging from 2234 to 2994 cell / mm², with standard deviation of 241.87 cell / mm² (Table no: 2). There was no statistically significant difference in preoperative endothelial cell counts in two groups, p value = 0.467.

In group A, first post operative day mean endothelial cell count was 2553.70 cell / mm², ranging from 2075 to 2751 cell / mm², with standard deviation of 124.32 cell / mm². The mean cell loss was 5.27% (4.75-7.23%) with standard deviation of 0.64%. In group B, first postoperative day mean endothelial cell count was 2476.12 cell / mm², with range of 2079-2802 cells / mm² and standard deviation of 224.50 cell / mm². The mean loss was 7.09% (5.95-7.80%) with standard deviation of 0.55% and a statistically significant difference of p=0.045.

In group A, third postoperative month mean endothelial cell count was 2515.70 cell / mm² ranging from 2047 to 2704 cell / mm² with standard deviation of 125.93 cell / mm². The mean loss was 6.44% (5.90-8.29%) with standard deviation of 0.62%. In group B, third postoperative month mean endothelial cell count was 2436.92 cell / mm², with range of 2047-2770 cells/mm² and standard deviation of 228.50 cell / mm². The mean loss was 8.39% (6.89-9.75%) with standard deviation of 0.61 %. (Graph 1 & 2). There was statistically significant difference (p=0.039) in third postoperative month endothelial cell counts between the two groups.

Table 1: Demographic data

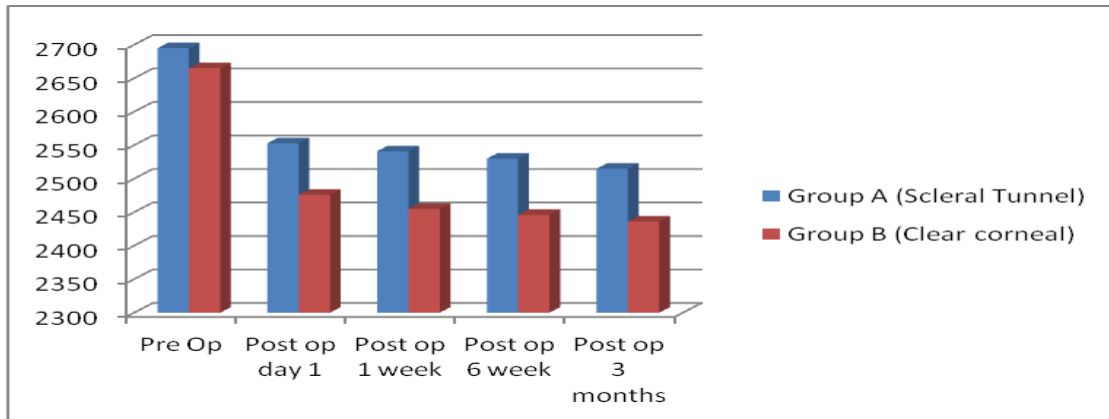
	Group A (n=50)	Group B (n=50)
Age	45-65 Years mean 54.76	45-65 Years mean 54.88
Gender	Male. 21 (42%) Female. 29 (58%)	Male. 23 (46%) Female. 27 (54%)
Laterality	Right Eye. 27 (54%) Left Eye. 23 (46%)	Right Eye. 29 (58%) Left Eye. 21 (42%)

Table 2: Preoperative endothelial cell count (n=100)

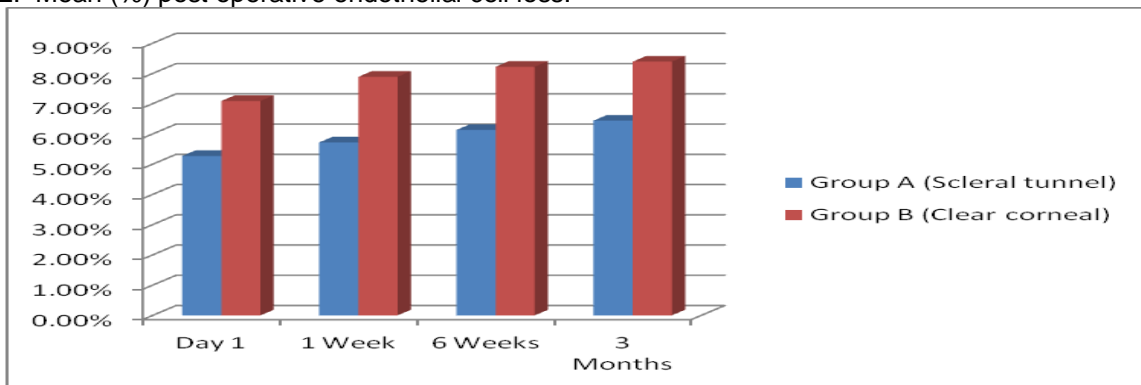
Group	=n	Range (cells/mm ²)	Mean (cells/mm ²)	SD (cells/mm ²)	p value
A(sclera tunnel)	50	2215-2896	2695.30	131.403	0.467
B(clear corneal)	50	2234-2994	2665.82	241.87	

p value > 0.05 is not significant

Graph 1: Mean endothelial cell count.



Graph 2: Mean (%) post operative endothelial cell loss.



DISCUSSION

The normal thickness and transparency of the cornea are maintained by the barrier function and the active fluid pump of the corneal endothelium¹⁴. Corneal endothelial cells can be damaged by many factors during and after cataract surgery. Intraoperative factors associated with corneal endothelial injury include bubble and free radical formation during phacoemulsification, ultrasound energy, mechanical trauma by instruments, presence of lens fragments and intraocular lens. Endothelial alterations are considered important parameters of surgical trauma and are essential in estimating of surgical techniques¹⁵.

There was no statistically significant difference in preoperative endothelial cell counts between the

two groups. There was statistically significant difference in post operative endothelial cell counts between the two groups at all follow up visits. Scleral tunnel incision group resulted in 6.44% ± 0.62% mean cell loss 3 month postoperatively. Mean cell loss 3 month postoperatively was 8.39% ± 0.61% by clear corneal incision. The result clearly showed that scleral tunnel incision was less damaging to the endothelial cells.

In this study a progressive decrease in cell density was noted during the three month follow up. It is emphasized that it is not clear how long it takes the endothelial cell count to stabilize after cataract surgery. There are reports of cell loss stabilization three months after uneventful cataract surgery^{16, 17}. There is evidence of continuing cell loss even several

years after surgery despite apparent normalization of endothelial morphologic characteristics^{18,19}.

The results in the literature on mean cell loss after phacoemulsification are not homogenous. Other studies of uneventful phacoemulsification report a mean endothelial cell loss of 12.03%⁸⁹, 18.3%⁹⁰ and 8.5% three months after a superior limbal incision²⁰. Kohlhass and coauthors²¹ report an approximate 18% cell loss at the center and 27% at the 12 o'clock position 1 year after phacoemulsification.

Ravalico et al, in a study of 40 cases, have assessed the endothelial function after ECCE and phacoemulsification. They found a decrease in endothelial cell density at 30 days post surgery by 10.1 % in cases of ECCE and 8.5 % in cases of phacoemulsification²².

One study conducted by Werblin TP demonstrated that routine uncomplicated phacoemulsification surgery demonstrated a 9% endothelial cell loss 1 year postoperatively.²³ It is difficult to compare our results with these data for two reasons. First Intraoperative and postoperative endothelial injury depends on a combination of factors²⁴. Second specular microscopy can determine the cell count with a standard deviation of 5.0%²⁵ and calculating endothelial cell loss can be difficult²⁶.

For the same size scleral tunnel incision our data showed less endothelial cell damage (6.44% ± 0.62%) than the data of Diaz-Valle et al²⁷ who reported a mean cell loss of 11.8% three months after 5.5 mm scleral tunnel phacoemulsification. For the same size temporal clear corneal incision, our results, 8.39% ± 0.61% mean cell loss, appears similar to the results of Dick and coauthors²⁸ who found a mean reduction in endothelial cellular density of 7.9%.

This study showed less endothelial cell loss as compared to the results of Giorgio Beltrame and coauthors²⁹. They reported mean endothelial cell loss of 22% by 5.5mm clear corneal incision at 3 month follow up. They also reported 17% mean endothelial cell loss by scleral tunnel incision at 3 month follow up. Scleral tunnel incision resulted in statistically significant less postoperative endothelial cell loss as compared to clear corneal incision. Our result was comparable to the result of Giorgio Beltrame and coauthors²⁹ as in our study scleral tunnel incision resulted in less endothelial loss than the clear corneal incision.

We believe, as suggested by others³⁰, that the higher cell loss in the clear corneal incision group might be caused by mechanical trauma from the phaco tip or instruments used to insert IOL, despite the use of viscoelastic material. Compared with clear corneal incision, scleral tunnel incision was associated with lower postoperative endothelial

damage. This is probably because the scleral tunnel is more posterior and therefore induces less direct (e.g., phaco tip, IOL implantation) and indirect (mechanical corneal striae) trauma.

CONCLUSIONS

The study shows that phacoemulsification is a safe procedure in experienced hands. Compared with clear corneal incision, scleral tunnel incision is associated with lower postoperative endothelial damage. It is suggested that scleral tunnel incision should be used in patients at risk for endothelial damage in cataract surgery.

REFERENCES

1. Kanski JJ. Clinical Ophthalmology. 5th ed. India: Butterworth Heinemann; 2003.
2. Zaman M, Iqbal S, Khan Y M, Khan M T, Jadoon M Z, Qureshi M B, et al. Manual small incision cataract surgery (MSICS). Review of first 500 cases operated in microsurgical training center. Pak J Ophthalmol 2006; 22:14-22.
3. Khan A Q, Qureshi B, Khan M D. Rapid assessment of cataract blindness in age 40 years and above in District Skardu, Baltistan, Northern Areas of Pakistan. Pak J Ophthalmol 2003; 19:84-9.
4. Qazi ZA. Corneal endothelium tissue that demands respect [editorial]. Pak J Ophthalmol 2003; 19:1-2.
5. Ahmad A, Ahmad J. Combined phacoemulsification, intraocular lens implantation and trabeculectomy. Pak J Ophthalmol 2000; 16: 26-8.
6. Yi DH, Sullivan BR. Phacoemulsification with indocyanine green versus manual expression extracapsular cataract extraction for advanced cataract. J Cataract Refract Surg 2002; 28: 2165-9.
7. Chakrabarti A, Singh S. Phacoemulsification in eyes with white cataract. J Cataract Refract Surg 2000; 26: 1041-7.
8. Beltrame G, Salvat ML, Driussi G, Chizzolini M. Effect of incision size and site on corneal endothelial changes in cataract surgery. J Cataract Refract Surg 2002; 28: 118-25.
9. Ishikawa A. Risk factors for reduced corneal endothelial cell density before cataract surgery. J Cataract Refract Surg 2002; 28: 1982-92.
10. Lee J S, Lee J E, Choi H Y, Oum B S, Cho B M. Corneal endothelial cell change after phacoemulsification relative to the severity of diabetic retinopathy. J Cataract Refract Surg 2005; 31:742-9.
11. Klyce SD, Beuerman RW. Structure and function of the cornea. In: Kaufman HE, Barton BA, McDonald MB, Waltman SR, editors. The cornea. New York: Churchill Livingstone; 1988.
12. Laing R, Sandstrom M, Leibowitz H. Clinical specular microscopy; Optical principles. Arch Ophthalmol. 1979; 97:1714.
13. Bourne WM, Kaufman HE. Specular microscopy of the human corneal endothelium in vivo. Am J Ophthalmol. 1976; 81: 319.

14. Tuft SJ, Coster DJ. The corneal endothelium. *Eye* 1990; 4: 389-424.
15. Werblin TP. Long term endothelial cell loss following phacoemulsification: model for evaluating endothelial damage after intraocular surgery. *Refract Corneal Surg* 1993; 9: 29-35.
16. Kosrirukvongs P, Slade SG, Berkeley RG. Corneal endothelial changes after divide and conquer versus chip and flip phacoemulsification. *J Cataract Refract Surg* 1997; 23:1006-1012.
17. Galin MA, Lin LL, Fetherlof E, et al. time analysis of corneal endothelial cell density after cataract extraction. *Am J Ophthalmol* 1979; 88:93-96.
18. Bourne WM, Nelson LR, Hodge DO. Continued endothelial cell loss ten years after lens implantation. *Ophthalmology* 1994; 101:1014-1022.
19. Bates AK, Cheng H. Bullous keratopathy: a study of endothelial cell morphology in patients undergoing cataract surgery. *Br J Ophthalmol* 1998; 72: 409-412.
20. Revalico G, Tongnetto D, Palomba MA, et al. Corneal endothelial function after extracapsular cataract extraction and phacoemulsification. *J Cataract Refract Surg* 1997; 23: 1000-1005.
21. Kohlass M, Stahlhurt O, Tholuck J, Richard G. Entwicklung der Hornhautdicke und-endothelzeldichte nach Kataraktextraktion mittels phacoemulsifikation. *Ophthalmologie* 1997; 94: 515-518.
22. Ravalico, Tagnetto. Endothelial cell loss after ECCE and Phacoemulsification. *J Cataract Refract Surg* 1997; 23:1000-06.
23. Werblin TP. Long-term endothelial cell loss following phacoemulsification: model for evaluating endothelial damage after intraocular surgery. *Refract Corneal Surg.* 1993 Jan-Feb; 9(1): 29-35.
24. Hayashi K, Hayashi H, Nakao F, Hayashi F. Risk factors for corneal endothelial injury during phacoemulsification. *J Cataract Refract Surg* 1996; 22:1079-1084.
25. Kohnen T. Corneal endothelium: an important structure for cataract and refractive procedures (editorial). *J Cataract Refract Surg* 1997; 23:967-968.
26. Hayashi K, Nakao F, Hayashi F. Corneal endothelial cell loss after phacoemulsification using nuclear cracking procedures. *J Cataract Refract Surg* 1994; 20:44-47.
27. Diaz-Valle D, Benitez del Castillo Sanchez JM, Castillo A, et al. Endothelial damage with cataract surgery techniques. *J Cataract Refract Surg* 1998; 24: 951-955.
28. Dick HB, Kohnen T, Jacobi FK, Jacobi KW. Long term endothelial cell loss following phacoemulsification through a temporal clear corneal incision. *J Cataract Refract Surg* 1996; 22: 63-71.
29. Giorgio Beltrame, MD, Maria L. Salvetar, MD, Giobatta Driussi, MD, Marzio Chizzolini, MD. Effect of incision size and site on corneal endothelial changes in cataract surgery. *J Cataract Refract Surg* 2002; 28: 118-125.
30. Kraff MC, Sanders DR, Lieberman HL. Specular microscopy in cataract and intraocular lens patients; a report of 546 cases. *Arch Ophthalmol* 1980; 98: 1782-1784.