

Role of Intravenous Soft Laser Therapy in the Treatment of Diabetic Foot Ulcers

MUHAMMAD LATIF AFTAB, ASMA RASHID*, MUHAMMAD ASLAM, RIFQA AWAN, MALEEHA ALTAF

ABSTRACT

Objectives: To find out the efficacy of the intravenous soft laser therapy in the treatment of diabetic foot ulcers.

Study design: It is a prospective study.

Materials and method: This study was conducted on 20 patients of both sexes suffering from diabetic foot ulcers. The patients were assessed clinically and surgical evaluation was done. Intravenous soft laser therapy was done. "Latif Aftab Connector" was used. The treatment was given on alternate days, 15 to 25 sessions were made depending on severity of lesion and response to treatment.

Results: Outcome was assessed predominantly on improving of the size of ulcers. No complication of the procedure observed during study.

Conclusion: Intravenous soft laser therapy is one of the important and reliable modality regarding the treatment of diabetic foot ulcer and prevention of amputation.

Key words: Soft Laser, Intravenous, Diabetic Foot Ulcers, Amputation.

INTRODUCTION

Soft laser light acts on the mitochondria in the cell and enhances the production of ATP. This increased cell energy accelerates the healing power of the wound by regeneration of blood vessels thus stimulation of microcirculation¹. It is claimed that the healing time of wound decreases by more than 50%, when soft laser light is used compared to the wound where it is not used². The soft laser should not be confused with the hard laser. The hard laser can cut, vaporize and coagulate the tissues and has thermal effects, whereas soft laser does not have thermal effects, due to this reason, it is also known as cold laser. The soft laser is human friendly; it relieves pain³, subsides inflammation and enhances wound healing processes⁴. It is also known as bio stimulating laser as it accelerates the endogenous biochemical processes in the cells leading to favorable biological effects in the tissues.

In Europe, America and Australia, soft laser therapy is a well accepted method to treat sports injuries⁵, Traumatic, inflammatory and overuse injuries, pain relief and healing of rheumatic and arthritic lesions⁶. It is also a useful modality in the treatment of persistent non healing wounds, cold sores and ulcers. Soft lasers have been used for over 35 years in many countries as therapeutic energy to bring about favorable biological effects.

The first soft lasers received FDA clearance in the United States in 2002. In the last few years, the

soft laser therapy in North America is being used increasingly. FDA has recently cleared many soft laser devices for treatment of a number of medical conditions, such as cervical neck pain, shoulder pain, low back pain, joint pain, generalized pain and acceleration of wound healing. This type of light therapy is being used in Governmental agencies in USA such as NASA⁷. Soft laser therapy is a regular feature in US Olympic training centers and some studies have reported very good results and recovery in sports injuries⁵. Soft laser light causes release of anti inflammatory enzymes and endorphins which are known as natural pain killers and mood elevators. Palmgren² investigated the effect of soft laser therapy on infected abdominal wounds after surgery. Healing time was less than half, 6-8 days laser group compared to 14 days where no laser therapy was used. Where as the use of soft lasers in skin lesions is now a days a routine, recognized method of wound healing in west^{4,9,10}. The Use of soft lasers on skin in diabetic foot has shown some valuable results^{1,11}. In this study, soft laser was used intravenously in diabetic foot ulcer patients to evaluate and assess its efficacy.

MATERIALS AND METHODS:

This study was conducted on 20 patients of both sexes suffering from diabetic foot ulcers. Intravenous soft laser therapy was done. To make the contact of the laser light with blood, world's 1st cheapest connector was designed and made by the principal investigator designated as "Latif Aftab Connector" for intravenous soft laser therapy. The connector on one

Department of Surgery and Pathology. Fatima Jinnah Medical College/Sir Ganga Ram Hospital Lahore
Correspondence to Dr. Muhammad Latif Aftab, Associate Professor Surgery email: drlatif_aftab@hotmail.com*

side accommodated intravenous cannula and on the other side tip of laser probe was introduced inside the connector. The source of the laser light was a soft laser device LaserCat marketed by Med Solution Germany. On average treatment was started with 20 mw red & infrared laser for 6 minutes. The dose was increased to 30mw red and infrared lasers gradually. The treatment was given on alternate days, 15 to 25 sessions were made depending on severity of lesion and response to treatment. Weekly assessment regarding improvement or otherwise was made on following parameters i.e., pin, coldness, numbness, praesthesia, ulceration, platelets aggregation, and duplex scan. The diabetic foot ulcers were classified according to Wagner's classification¹².

RESULTS

Twenty patients were included in this study to evaluate the efficacy of intravenous soft laser therapy on the treatment of diabetic foot ulcers. With reference to the Wagner's classification for the diabetic foot ulcers, the distribution of the patients is shown in table.

Table showing patients distribution according to Wagner's staging.

Wagner's stage	Number of patients
0	0
1	7
2	6
3	0
4	6
5	1
Total	20

Outcome was assessed predominantly on the improving of the size of ulcers. The duration of ulcers before therapy were ranging from 6 to 15 months. The number of sessions of intravenous soft laser therapy was ranging from 15 to 25, depending upon the severity of the lesion and the response of the treatment. The duration of the treatment was ranging from 30 to 50 days, again depending upon the severity of the lesion and the response of the treatment. Up to the stage 3, all patients responded well and were cured. However in two patients, recurrence of ulcer occurred, which responded well to the retreatment. In stage 4, feet of all patients were saved, but one patient has ray amputation of one toe before the start of soft laser therapy. However the rest of the foot was saved with the use of intravenous soft laser therapy. In stage 5, patient ultimately needed amputation of the foot. No complication of the procedures observed during study.

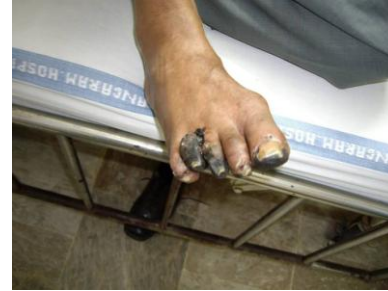

Figure 1: The First patient of the Study, Wagner's Stage 4

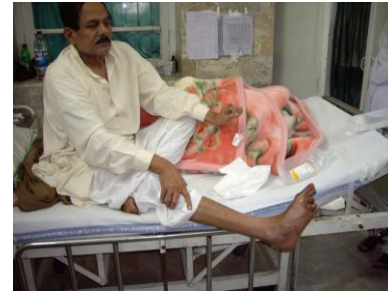

Figure 2: Close view of foot of the same patient

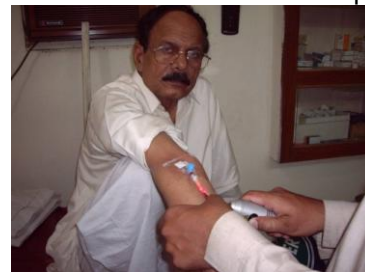

Figure 3: Ever First Intravenous Soft laser therapy of the patient in progress (24th April 2006)

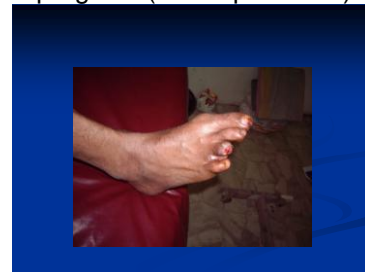


Figure 4: Post Intravenous Soft Laser Therapy (Close View)



Figure 5: Four years follow up of the same patient

DISCUSSION

Diabetic foot is one of the major complications of long standing diabetes mellitus. With existing treatment modalities, most of the patients will end up ultimately with some sort of amputation. In this study, intravenous soft laser therapy was used to cure diabetic foot ulcers and to avoid its progression to amputation, which has shown encouraging outcome. The problem in designing this study was “how to irradiate blood with soft laser light?”, as neither the laser device manufacturer (Med Solution-Germany), manufactured catheter to bring laser to come in contact with blood, nor other such catheter was available in this part of the world. To make the contact of the laser light with blood, world’s 1st cheapest connector was designed and made by the principal investigator designated as “Latif Aftab Connector” for intravenous soft laser therapy. The ever first patient in whom the intravenous soft laser therapy was used, was advised amputation by many consultants, but patient was reluctant. After evaluation, the ray amputation of one of the completely gangrenous toe was done. Later on this patient, after getting the formal consent was included in the study for intravenous soft laser therapy. This therapy was done on alternate days for 7 weeks and ultimately very encouraging results were seen, as the rest of the foot was saved. The four years follow up of the patient is available which shows a normal foot with no complaints. As shown in the results of this study, in other cases also the response of the therapy in diabetic foot ulcers was very good. On extensive search of the literature, although use of soft laser in diabetic foot on the skin shows encouraging results (1), (7), (10) but its intravenous use is not found in diabetic foot patients.

CONCLUSION

Intravenous soft laser therapy is one of the important and reliable modality regarding the treatment of diabetic foot ulcer and prevention of amputation.

REFERENCES

1. Schindl A, Schindl M, Pernerstorfer-schon H et al. Diabetic neuropathic foot ulcer” Successful treatment by low intensity laser therapy. *Dermatology*. 1999; 198:314-317.
2. Palmgren N. Low Level Laser Therapy of infected abdominal wounds after surgery. *Lasers Surg Med*. 1991; Suppl 3:11.
3. Tam G. Low Power Laser Therapy and Analgesic Action. *Journal of Clinical Laser Med & Surg*. 1999; 17 (1); 29-33.
4. Mendez T; Pinheiro A; Pacheco M et al: Dose and wavelength of Laser Light have influence on the repair of cutaneous wounds. *Journal of clinical Laser Medicine & Surgery*. 2004; 22(1): 19-25.
5. Simunovic Z; Trobonjaca T; Trobonjaca Z. Treatment of Medial and Lateral Epicondylitis—Tennis and Golfer's Elbow—with Low Level Laser Therapy: A Multicenter Double Blind, Placebo-Controlled Clinical Study on 324 Patients. *J Clin Laser Med & Surg*. 1998; 16 (3) : 145-151.
6. Longo L. Simunovic Z; Postiglione M. et al. Laser therapy for fibromyositic Rheumatism, *J Clin Laser Med & Surg*. 1997 ; 15 (5) : 217-220.
7. Harry T. Whelan MD; Ellem V. et al. “Effect of NASA light emitting diode irradiation on molecular changes for normal healing in diabetic mice. *Journal of Clinical Laser Medicine & Surgery*. 2004; 21 :2 ;67-74.
8. Ozdermir F; Birtane M; Kokino S. “The clinical efficacy of Low power laser Therapy on pain and function in cervical osteoarthritis. *Clinical Rheumatology*. 2001; : 20 930; 181-4.
9. Woodruff LD; Bounkeo JM; Brannon WM; “The efficacy of Laser therapy in wound repair, a meta-analysis of literature. *Photo med Laser Surg*, 2004; 22(3): 241-7.
10. Enwemeka CS; Pasker JC; Dowdy DS. et al. “The efficacy of low power lasers in tissue repair and pain control: a Meta Analysis study. *Photo med Laser Surg*,2004; 22(4): 323-9.
11. Landau Z. “Tropical Hyper baric oxygen and low energy laser for the treatment of diabetic foot ulcers.” *Archives of orthopedic and trauma surgery*. 1998; 117 (3); 156-8.
12. Brodsky JW. Staging and classification of foot lesions in diabetic patients. In Levin & O’neals; the diabetic foot, 6th edition, Mosby, Inc.2001;273-75.