

Primary Repair without Drain after Limited Excision of Pilonidal Sinus

HABIB QADIR, AHSAN NAZIR, MUHAMMAD ASLAM, IMTIAZ RASOOL.

ABSTRACT

The purpose of this study was to demonstrate an easy and effective operation for pilonidal sinus and assess its safety. This study was conducted on the surgical floor of Jinnah hospital from January 2000 to December 2004. 200 consecutive patients (175 male, 25 female) with pilonidal sinus under went primary closure without drain after excision of pilonidal sinus under spinal or general anesthesia. The sinus was excised with an elliptical incision to include the sinus and all of its tracts. Adequate haemostasis was ensured the resultant wound was closed with through and through prolene no. 1 vicryl 2/0 was used for subcutaneous fat and prolene 3/0 for skin the resultant wound was in the midline No drain was used .the operations took 30 to 45 minutes. I/v Augmentin was given as prophylaxis for 48 hours and sitz baths were advised three times a day until the removal of sutures. Prolene no1 sutures were removed on the 10th postoperative day and skin sutures on the 14th postoperative day. The patients were advised to be very vigilant in shaving and cleaning the area. The follow up was on 10 and 14 postoperative days, 6months, 12 months, and 24 months postoperatively. Wound healing was achieved in14 days. Infection rate was only 3 percent. Primary closure after limited excision of pilonidal sinus without drain results in early healing and has a low infection rate

.Key words: Pilonidal sinus, primary closure, limited excision, without drain.

INTRODUCTION

Pilonidal sinus is a common disease afflicting young adults. It consists of complex symptoms ranging from pits to painful draining lesions mainly located in the sacrococcygeal region. Because of delayed healing by conventional methods and recurrences of this disease¹ optimal treatment strategy is still a matter of discussion².

Wide excision and healing by open granulation^{3,5} is favored by most surgeons due to simplicity of procedure and low rate of recurrence^{13,14}. However healing is delayed (8 to 12 weeks) and requires regular dressing and meticulous wound care Primary closure^{4,6} and fibrin glue closure⁷ have been described but have a high rate of recurrence⁹. Partial closure by marsupialisation is another option⁷. To obviate these problems more complex procedures like z- plasty , and myocutaneous flaps have been described¹⁰ .they reduce the recurrence rates but they need expertise, have longer operation times and postoperative hospital stays¹¹. Bascoms technique of cleft closure avoids wound in midline and has high success rate¹².Karydakis operation of asymmetrical excision and closure by use of advancing flap produces a small wound leading to early healing¹⁶. Radio frequency excision has also been described¹⁸. Limbergs rhomboid flap is another technique with low

rates of recurrence²⁹.

The aim of this paper is to describe a simple technique for limited excision and primary closure without drain and demonstrate low recurrence and infection rates.

PATIENTS AND METHODS

This study was conducted between January 2000 and December 2004 on 200 consecutive patients with chronic pilonidal sinus which included 175 male and 25 female patients. The ages were between 18 and 35 years. patients presenting with chronic pilonidal sinus were included in the study. Patients with actively draining sinuses were operated after a 5 day course of oral augmentin. Patients presenting with acute abscesses were excluded from the study

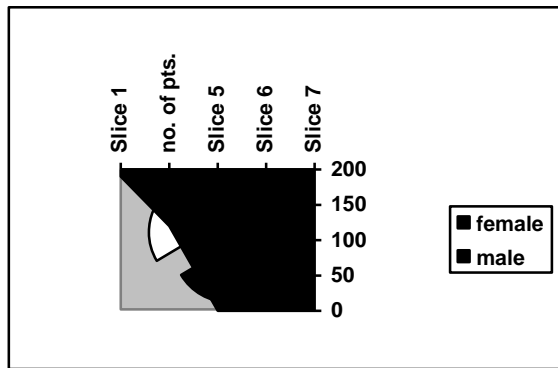
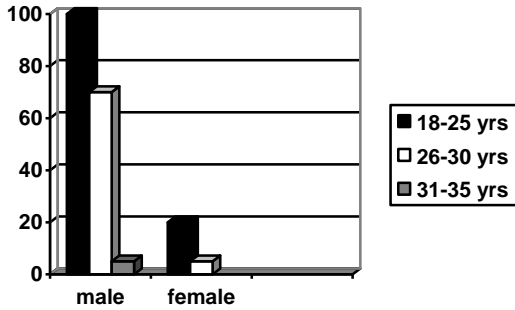
The operations were done under spinal or general anesthesia. The sinus was excised with an elliptical incision to include the sinus and all of its tracts. Adequate haemostasis was ensured the resultant wound was closed with through and through prolene no. 1 vicryl 2/0 was used for subcutaneous fat and prolene 3/0 for skin the resultant wound was in the midline. No drain was used .the operations took 30 to 45 minutes. I/v co-amoxiclav was given as prophylaxis for 48 hours and orally for three more days, and sitz baths were advised three times a day until the removal of sutures. Prolene no1 sutures were removed on the 10th day and skin sutures on

Department of Surgery, Allama Iqbal Medical College/Jinnah Hospital, Lahore
Correspondence to Dr. Habib Qadir, Email: drhabibshafi@gmail.com

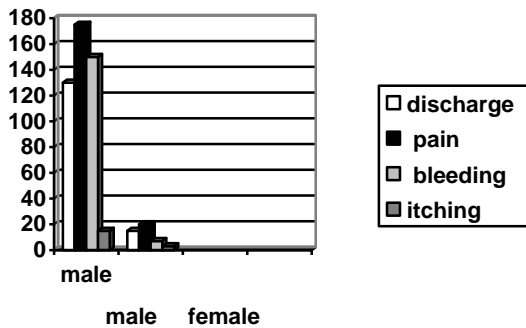
the 14th day. The patients were advised to be very vigilant in shaving and cleaning the area.

RESULTS

The age range and male female distribution is shown in figure below



The symptoms and there distribution is shown in the table below



The results in terms of operating time duration of hospitalization rate of infection and return to work are given below.

Mean operation time 45 minutes

Operation time	=n
30-40 minutes	165
41-50 minutes	25
51-60 minutes	10

Hospital stay

Hospital stay	=n
72 hours	170
96 hours	30

Period off work 12 days

Period of work	=n
10 days	50
12 days	120
14 days	30

Wound infection 6 patients (3%)
 Recurrences none

Six patients developed wound infection 3 patients had cellulites which responded to oral augmentin for 7 days the other 3 patients needed removal of 1-2 sutures and expression of purulent serosanguineous discharge along with oral augmentin for 10 days. No patient required laying open of the wound and there were no recurrences.

DISCUSSION

Numerous techniques have been described for primary closure after excision of pilonidal sinus. Recurrences vary with technique operator and length of follow-up¹⁹. An ideal surgical procedure should be simple to perform, have limited excision of tissues⁶, should have a low recurrence rate, short hospital stay coupled with a rapid and complete wound healing. It should have minimal after care requirements such as frequent hospital visits and dressings needing medical supervision²⁰.

It has been shown by researchers that pilonidal sinotomy is a good approach with a high cure rate^{16,24}. Limited excision of pilonidal sinus is shown to have shorter convalescence in comparison to more aggressive excisional methods^{6,27}. Limited closure with marsupialisation has also been described²³. A lay open method has also been described¹⁷.

Other approaches include Karydakis^{15,29}, Bascoms¹² and Limberg flap^{30,31}. All of these methods are technically more demanding, time consuming and have significant recurrence rates. Various complications of the operation have been described they include wound infection stitch sinuses and recurrence²¹.

Our technique is simple easy to use with low infection and recurrence rates. The reason that our technique has a lower recurrence rate as compared to other studies of simple primary closure⁹ is the use of through and through prolene sutures to obliterate the dead space³². Another reason could be the closure without drains²⁸. The use of Co-Amoxiclav for five days postoperatively also decreases the infection rate³³. The reason for early healing is limited excision of tissues^{6,27}. The patients get early healing of wound and return to there work earlier. The early healing makes it a much more acceptable option as

compared to open healing by secondary intention. A 24 month follow-up appears to be adequate to assess the efficacy and outcome of the procedure^{22,25,26}. Other studies support our view^{4,32}.

CONCLUSION

Primary repair of pilonidal sinus without drain after limited excision of pilonidal sinus is a safe option. It is a simple technique, has a shorter operating time, few complications, early healing which results in early discharge from hospital and early return to work.

REFERENCES

1. Flamein R, Slim K, Grandjean JP: Surgery of pilonidal sinus; what is the preferred technique? *Ann Chir* 2005; 139:573-576.
2. Menten O, Bagci M, Bilgin T, Coskun I, Ozgul O, Ozdemir M: Management of pilonidal sinus disease with oblique excision and primary closure: Results of 493 patients. *Dis Colon Rectum* 2006;49:104-108
3. Holmebakk T, Nasbakken A: Surgery for pilonidal disease. *Scand J Surg* 2005; 94:43-46.
4. Yigit T, yigitler C, Gulec B, Ihsan UA, Oner K. Do we need to use subcutaneous suture for pilonidal sinus treated with excision and primary closure? : *Acta Chir Belg.* 2005 Nov-Dec; 105(6); 635-638.
5. Blanco G, Giordano M, Torelli I: Surgical treatment of pilonidal sinus with open surgical technique. *Minerva Chir* 2003; 58:181-187.
6. Mohamed HA, Kadry I, Adly S: Comparison between three therapeutic modalities for non-complicated pilonidal sinus disease. *Surgeon* 2005;3:73-77
7. Seleem MI, Al-Hashemy AM: Management of pilonidal sinus using fibrin glue: a new concept and preliminary experience. *Colorectal disease* 2005; 7:319-322.
8. Spivak H, Brooks VL, Nussbaum M, Friedman L: Treatment of chronic pilonidal sinus disease. *Dis Colon Rectum* 1996; 39:1136-1139.
9. Iesalnieks I, Furst A, Rentsch M, Kaich KW: Primary midline closure after excision of pilonidal sinus is associated with a high recurrence rate *Chirurg* 2003; 74:461-468.
10. Chintapatia S, Safarani N, Kumar S, Haboubi N: Sacrococcygeal pilonidal sinus: historical review, pathological insight and surgical options. *Tech Coloproctol* 2003; 7: 3-8.
11. Lee HC, Ho YH, Seow CF, Eu KW, Nyam D: Pilonidal disease in Singapore: clinical features and management. *Aust NZ J Surg* 2000; 70:196-198.
12. Zorcolo L, Capra F, Scintu F, Casual G: Surgical treatment of pilonidal sinus disease. Results with Bascoms technique. *Minerva Chir* 2004; 58:387-395.
13. Cheidozi LC, Al-Rayyes FA, Salem MM, Al-Haddi FH, Al-Bidewi AA: Management of pilonidal sinus. *Saudi Med J* 2002; 23: 786-788.
14. Testini M, Piccinni G, Miniello S, Di Venere B, Lissidini G, Nicolardi V, Bonomo GM: Treatment of chronic pilonidal sinus with local anesthesia: a randomized trial of closed compared with open technique. *Colorectal Dis* 2001; 3 427-430.
15. Anyanwu AC, Hossain S, Williams A, Montgomery AC: Karydakos operation for sacrococcygeal pilonidal sinus disease: experience in a district general hospital. *Ann R Coll Surg Engl* 1998; 70: 197-199.
16. Lord PH, Millar DM: Pilonidal sinus: a simple treatment. *Br J Surg* 1965; 52: 298-300.
17. Al-Homoud SJ, Habib ZS, Abdul Jabbar AS, Isbister WH: Management of sacrococcygeal pilonidal disease. *Saudi Med J* 2001; 22: 762-764.
18. Gupta PJ: Radiofrequency incision and lay open technique of pilonidal sinus, *Kobe J Med Sci* 2003; 49: 75-82.
19. Hull TL, Wu J: Pilonidal disease. *Surg Clin N Am* 2002; 82: 1169-1185.
20. Destito C, Romagnoli A, Pucello D, Mercuri M. Pilonidal sinus: long term results of excision and closure technique; review of literature. *G Chir* 1997; 18: 441-446.
21. Zeiger K: Complications after surgery for pilonidal cyst: an introduction to a new debate on a costly disease. *Ugeskr Laeger* 1999; 161:6056-6058.
22. Petersen S, Koch R, Stelzner S, Wendlandt TP: Primary closure techniques in chronic pilonidal sinus: a survey of the results of different clinical approaches. *Dis Colon Rectum* 2002; 45: 1458-1467.
23. Oncel M, Kurt N, Kement M, Colak E, Eser M, Uzun H: Excision and marsupialisation versus sinus excision for treatment of limited chronic pilonidal sinus disease: a prospective, randomized trial. *Tech Coloproctol* 2002; 6: 165-169.
24. Al-Naami MY: Outpatient pilonidal sinotomy complemented with good wound and surrounding skin care. *Saudi Med J* 2005; 20:425-422.
25. Gencosmanglu R, Inceoglu R: Modified lay open (incision, curettage, partial lateral wall excision and marsupialisation) versus total excision with primary closure for treatment of chronic sacrococcygeal pilonidal sinus: a prospective, randomized clinical trial with a complete two year follow-up. *Int J Colorectal Dis* 2005; 20: 415-422.
26. Breuninger H: Treatment of pilonidal sinus and acne inversa. *Hautarzt* 2004; 55: 254-258.
27. Miocinovic M, Horzic M, Bunoza D: The treatment of pilonidal disease of the sacrococcygeal region by limited excision and open wound healing. *Acta Med Croatica* 2000; 54:27-31.
28. Erdem E, Sungurtekin U, Nessar M. Are post-operative drains necessary with the Limberg flap for treatment of pilonidal sinus? *Dis Colon Rectum* 1998; 41:1427-31.
29. Karydakos GE. Easy and successful treatment of pilonidal sinus after explanation of its causative process. *Aust NZ J Surg* 1992; 62:385-89.
30. Kapan M, Kapan S, Pekmezci S, Durgun V. Sacrococcygeal pilonidal sinus disease with Limberg flap repair. *Tech Coloproctol* 2002; 6(1) 27-32.
31. Katsoulis IE, Hibberts F, Carapeti AW: Outcome of primary and recurrent pilonidal sinuses with limberg flap. *Surgeon* 2006; 4: 7-10.
32. Aldean I, Shankar PJ, Mathew J, Safarani N, Haboubi NY. Simple excision and primary closure of pilonidal sinus: a simple modification of conventional technique with excellent results. : *Colorectal Dis.* 2006 Jan;7(1):81-5
33. Chaudri A, Bekdash BA, Taylor AL. Single dose metronidazole vs 5 day multi drug antibiotic regimen in excision of pilonidal sinuses with primary closure: a prospective randomized double blinded pilot study: *Int J colorectal dis.* 2005 Dec; 17:1-5.

